

## REFERRED PAIN

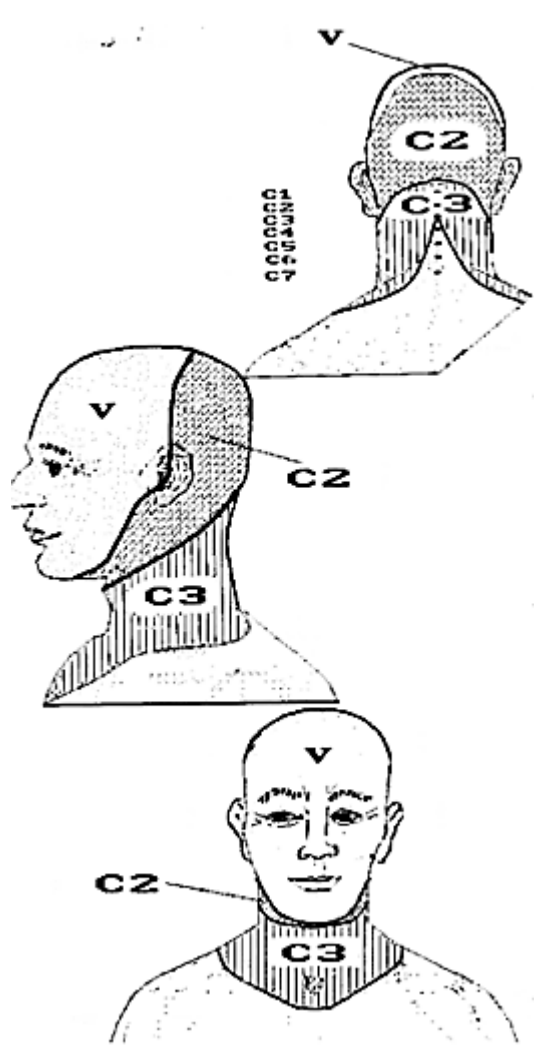
*Referred pain* is a painful sensation located in a part of the body that is usually considerably removed from the source of the pain. This type of pain most frequently radiates or refers from a muscle (trigger point formation), or irritated nerve root. It may also originate from a visceral organ, interspinous ligament or other deep sensory organ. Each source of referred pain generally produces a distinct referred pain pattern, but a referred pain pattern may not be exclusive. Referred pain patterns from

different sources may be simultaneously coincident, thus overlapping one another.

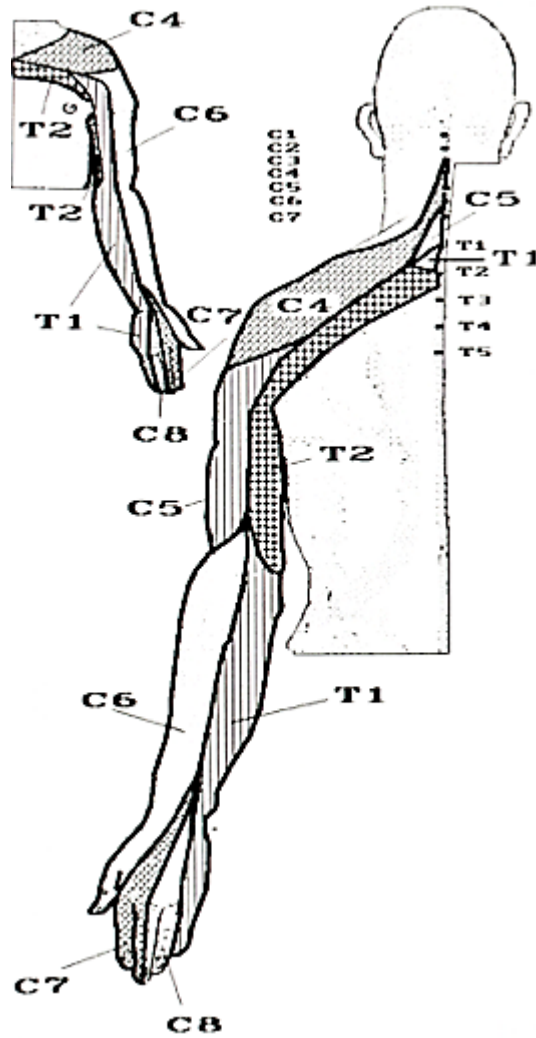
### **Treatment**

Treatment of *nerve root* or *ligamentous* sources of referred pain must be directed at relieving associated inflammation, swelling, adhesions, or other structural pressure (refer to Nerve Root or Dermatome Referred Pain Distribution, and Interspinous Ligamentous Referred Pain Patterns).

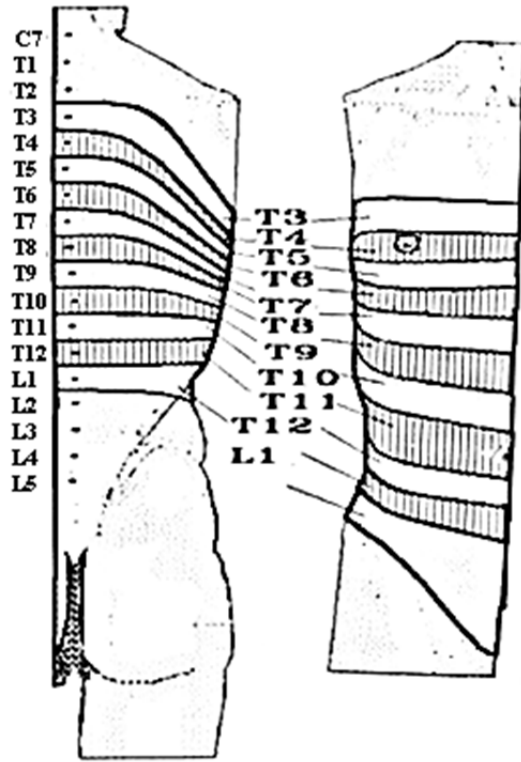
**NERVE ROOT OR DERMATOME REFERRED PAIN DISTRIBUTION**



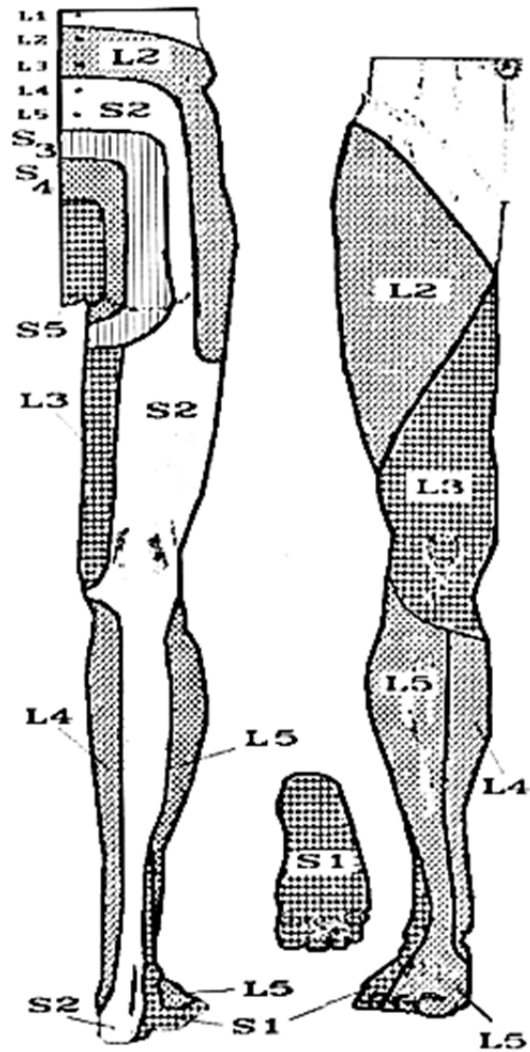
**Cutaneous Innervation of Cranial N. V (Trigeminal Nerve), C2 & C3**



**Cutaneous Innervation of C4-C8, T1 & T2**

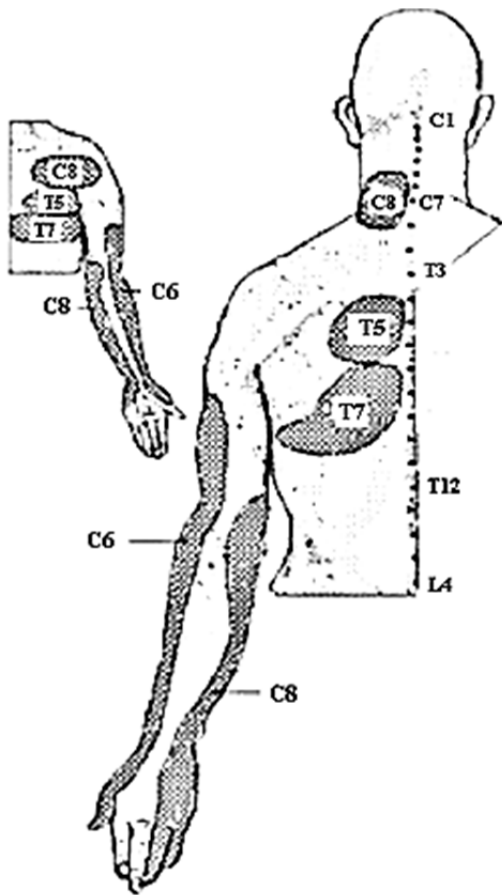


Cutaneous Innervation of T3-L1

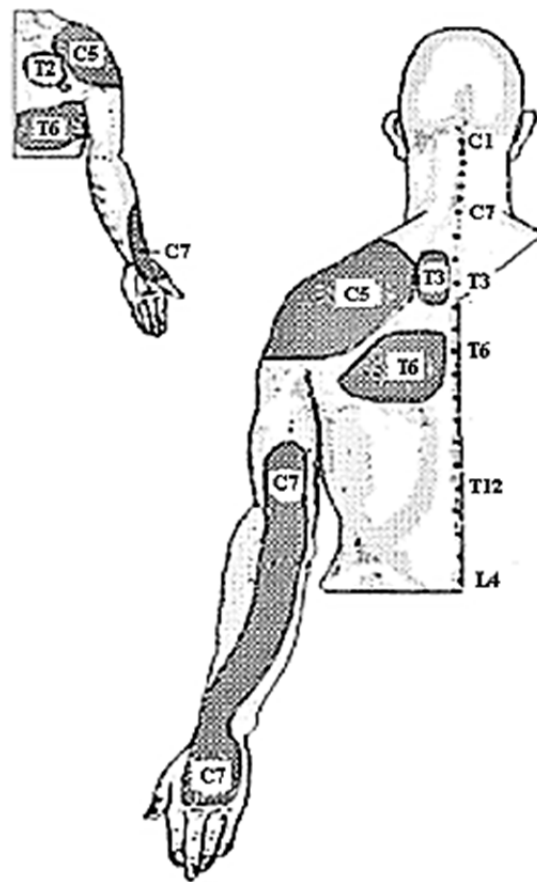


Cutaneous Innervation of L2-S2

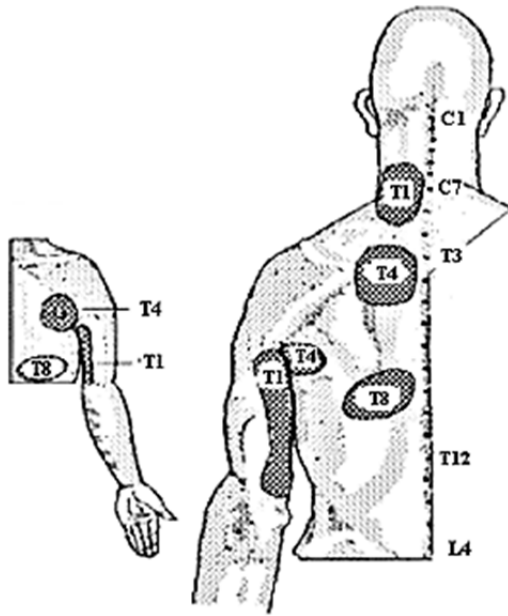
## INTERSPINOUS LIGAMENTOUS REFERRED PAIN PATTERNS



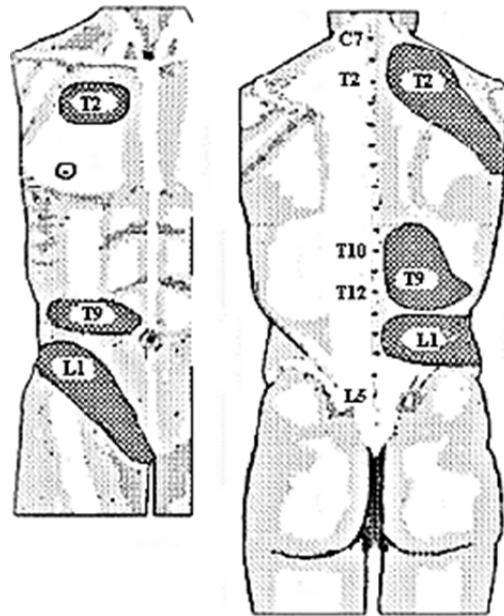
**Referred Pain Patterns from  
Interspinous Ligaments C6, C8, T5 & T7**



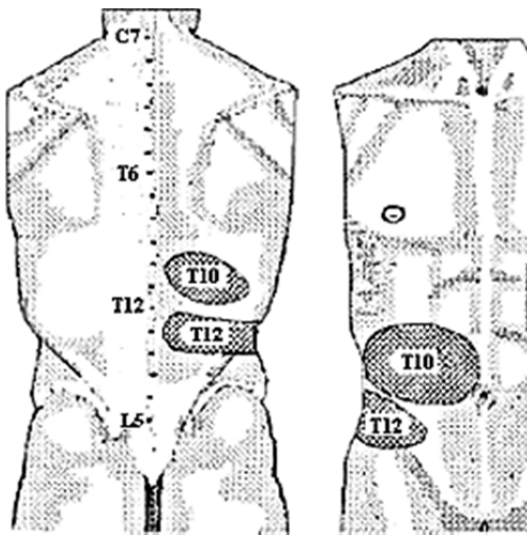
**Referred Pain Patterns from  
Interspinous Ligaments C5, C7, T3 & T6**



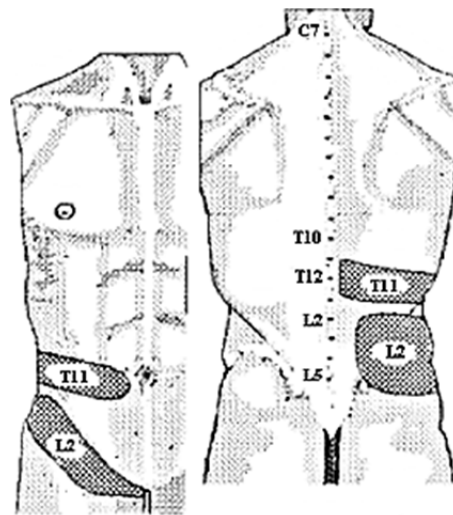
**Referred Pain Patterns from Interspinous Ligaments T1, T4 & T8**



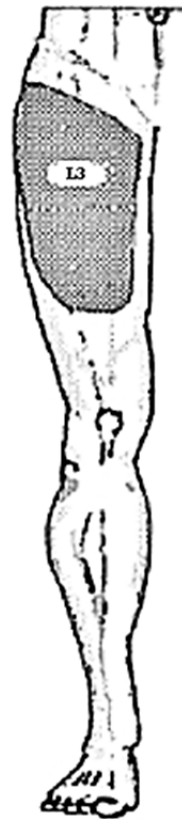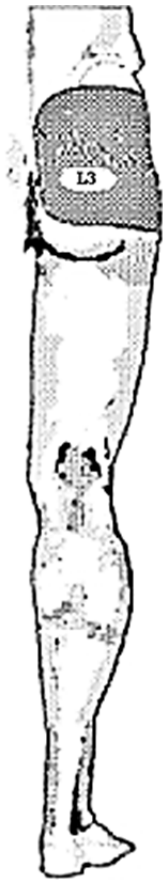**Referred Pain Patterns from Interspinous Ligaments T2, T9 & L1**



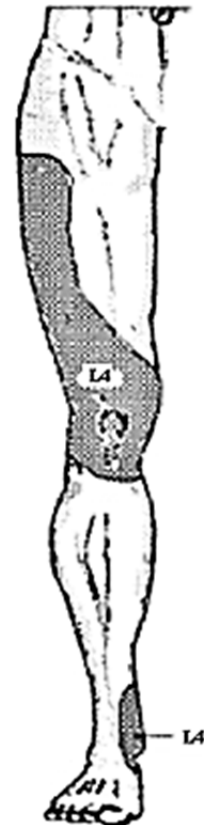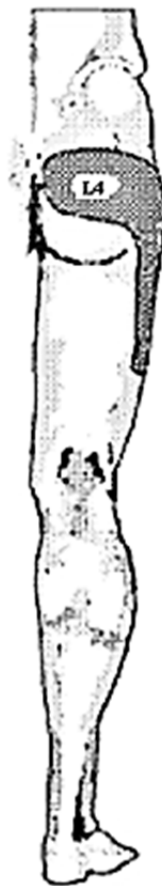**Referred Pain Patterns from Interspinous Ligaments T10 & T12**



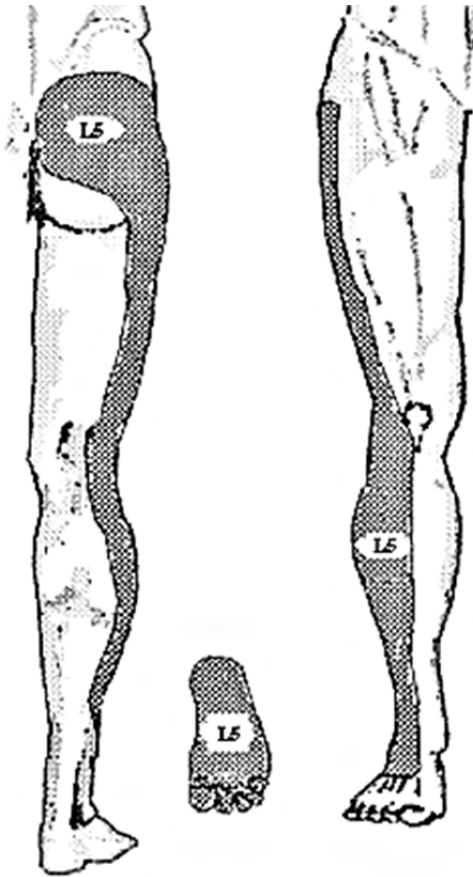
**Referred Pain Patterns from Interspinous Ligaments T11 & L2**



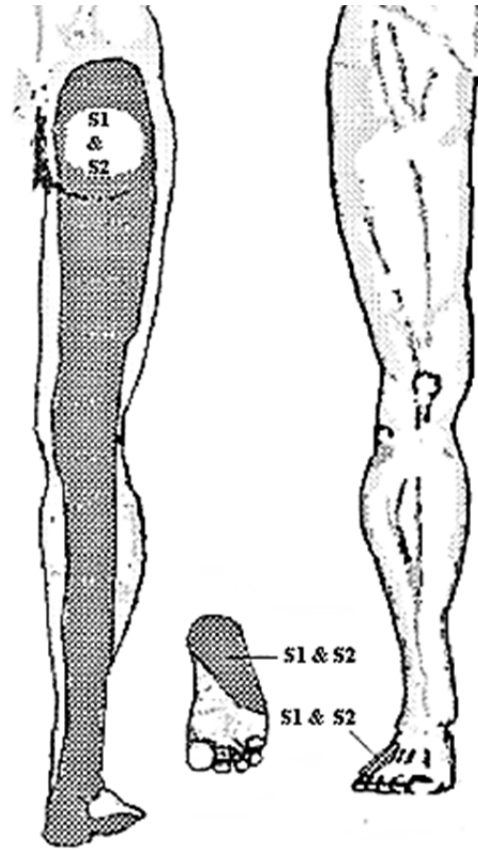
**Referred Pain Patterns from Interspinous Ligament L3**



**Referred Pain Patterns from Interspinous Ligament L4**

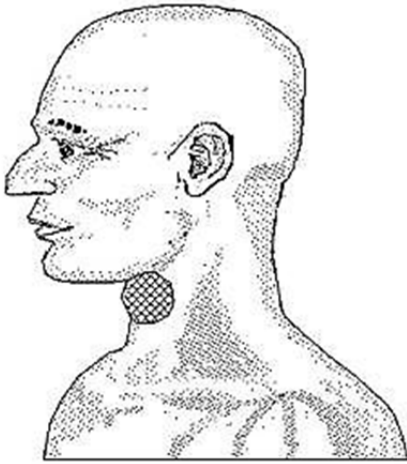


**Referred Pain Patterns from Interspinous Ligament L5**

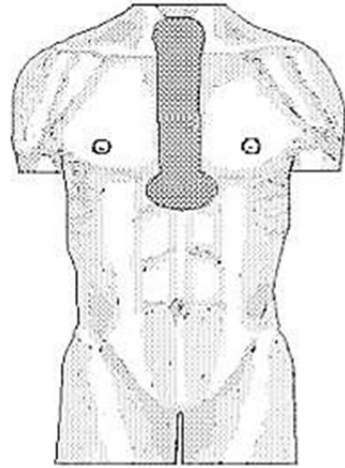


**Referred Pain Patterns from Interspinous Ligaments S1 & S2**

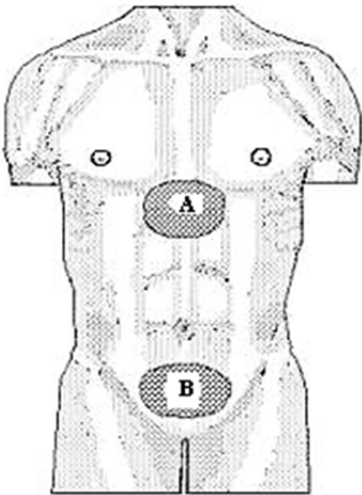
## VISCERAL ORGAN REFERRED PAIN PATTERNS



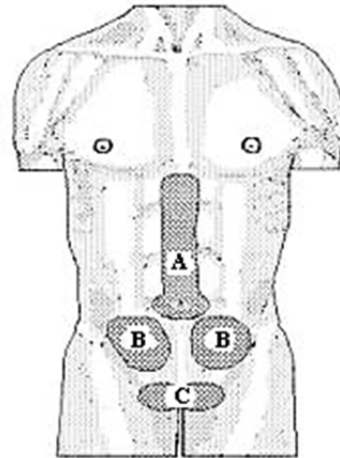
Referred pain patterns from the Larynx



Referred pain patterns from Upper Esophagus, Trachea, or Bronchi

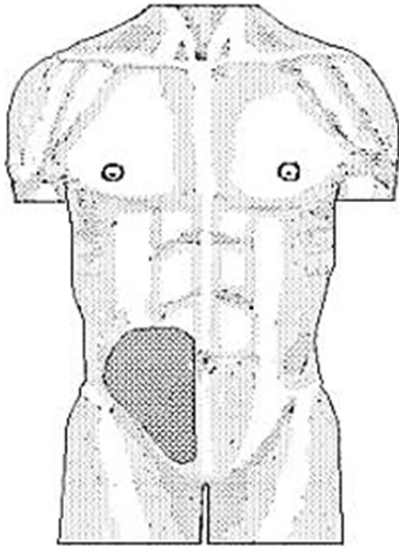


Referred pain patterns from Lower Esophagus, Gastric Cardia, Jejunum, Ileum or Duodenal Cap, (B) Lower Colon

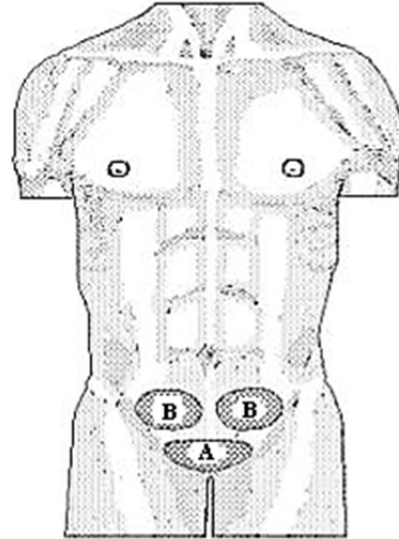


Referred pain patterns from the (A) Duodenum, (B) Upper Colon, (C) Testis

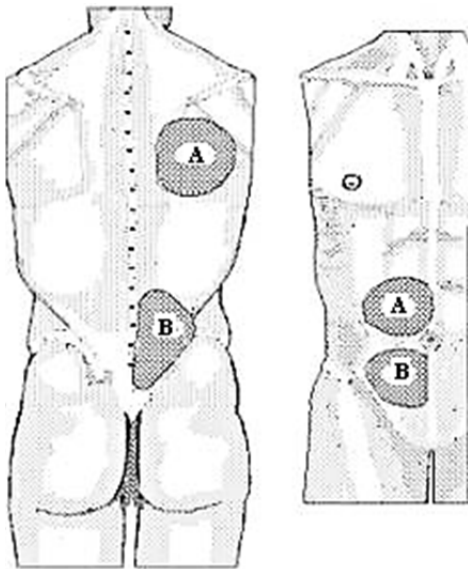




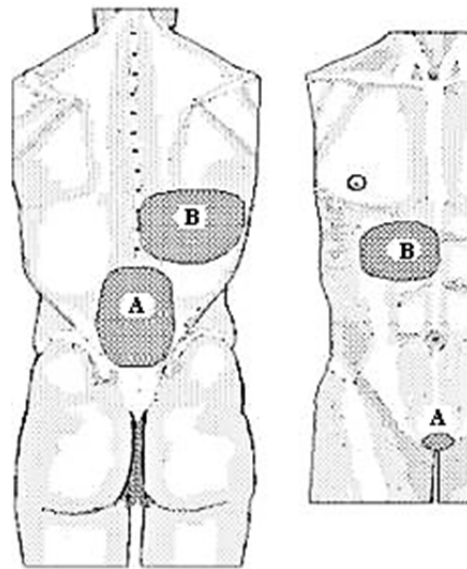
Referred pain pattern from the Appendix



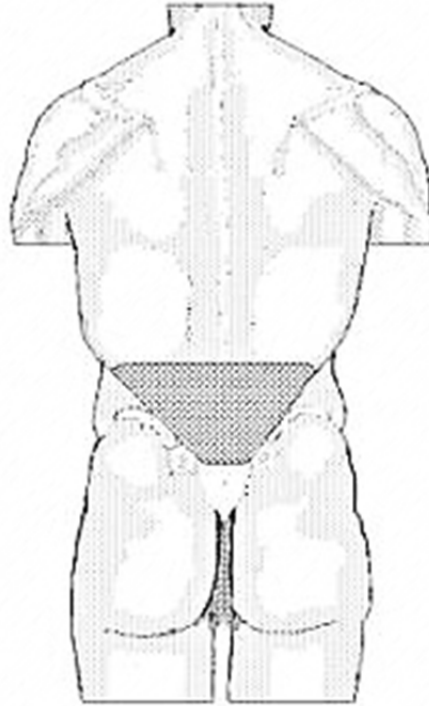
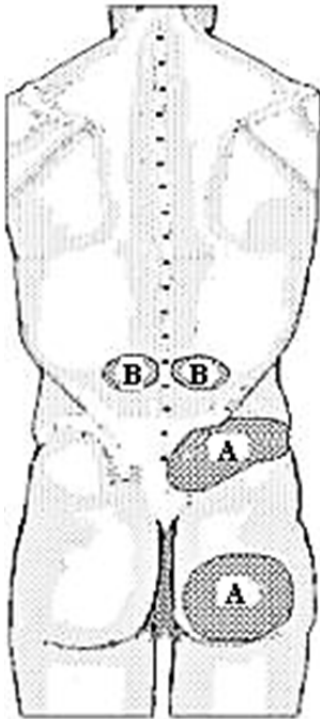
Referred pain patterns from the (A) Bladder Fundus, (B) Uterine Fundus



Referred pain patterns from the (A) Gallbladder, (B) Fallopian Tube or Ovary

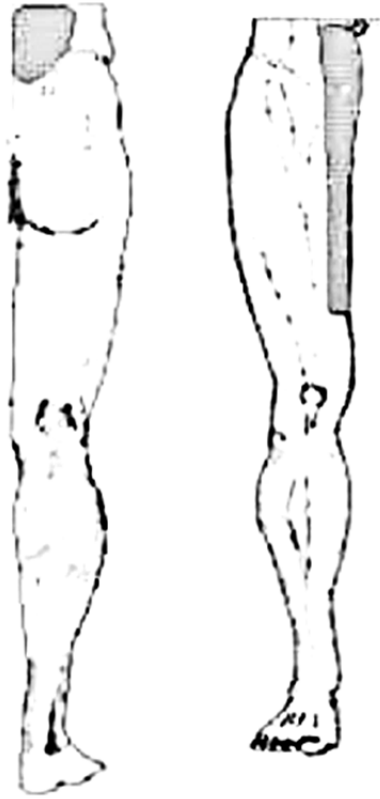


Referred pain patterns from the (A) Prostate Gland, (B) Pancreas




**Referred pain patterns from the  
(A) Bladder Neck, (B) Kidney Pelvis**

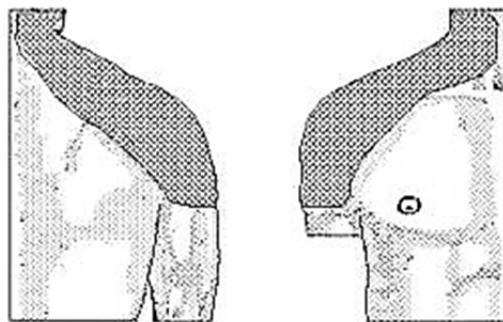
**Referred pain patterns from the  
Seminal Vesicles, Uterine Cervix or  
Upper Vagina**



**Referred pain patterns from the Ureter**

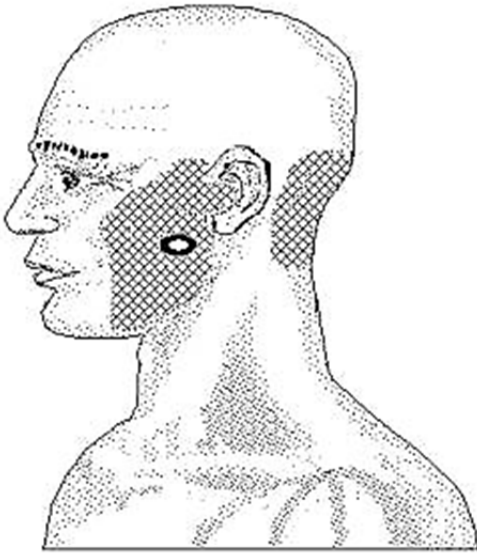


**Referred pain patterns from Myocardium**

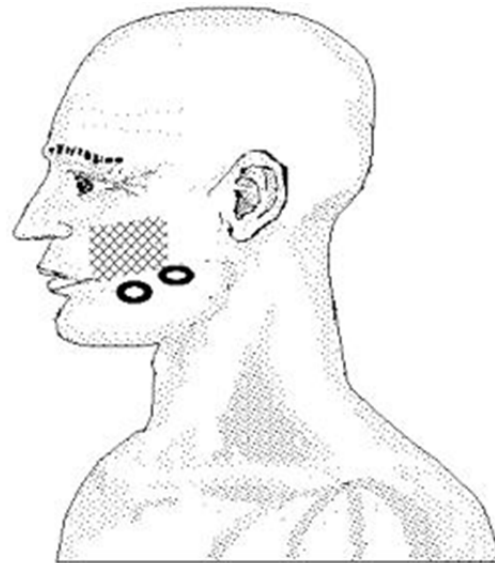


**Referred pain pattern from the Ascending Aortic Arch (aneurysm)**

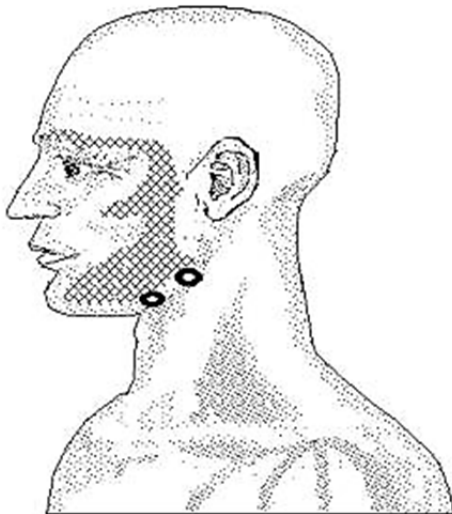
## TRIGGER POINT REFERRED PAIN PATTERNS



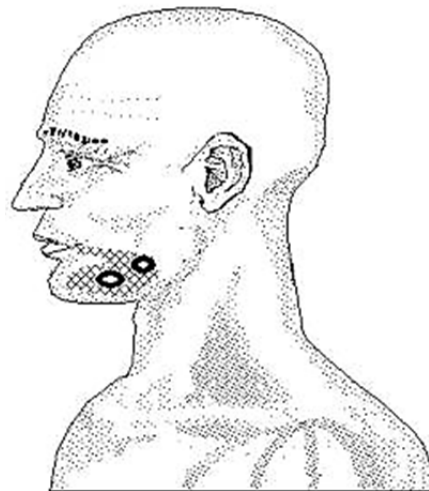
**Masseter (deep)**



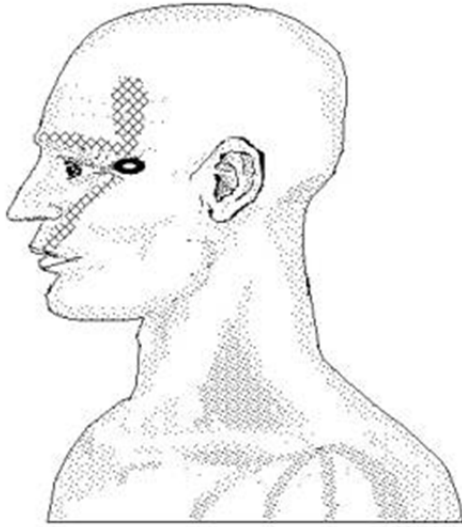
**Masseter (superficial A)**  
(pattern may include upper teeth & jaw)



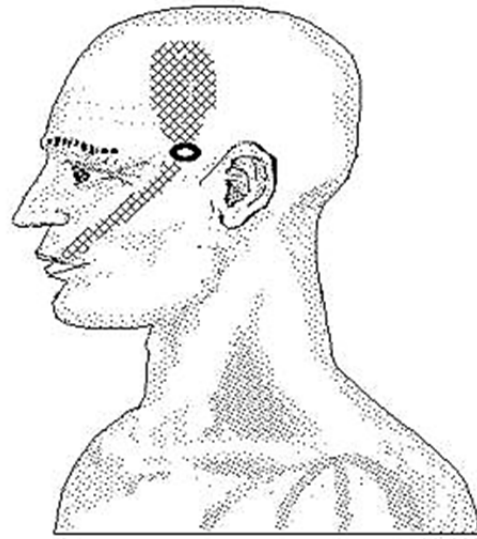
**Masseter (superficial B)**



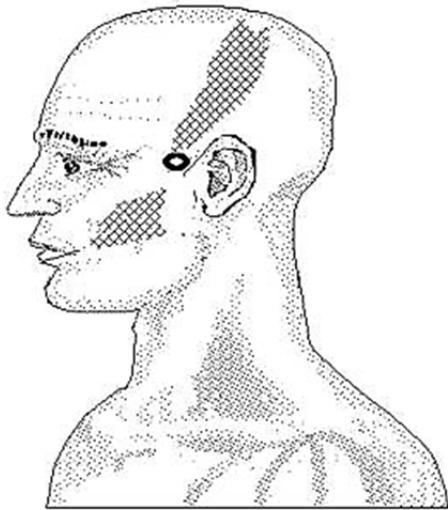
**Masseter (superficial C)**  
(pattern may include upper teeth & jaw)



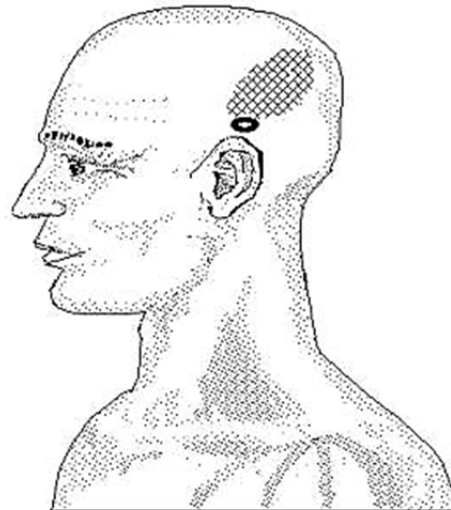
**Temporalis (anterior)**  
**(pattern may include upper teeth & jaw)**



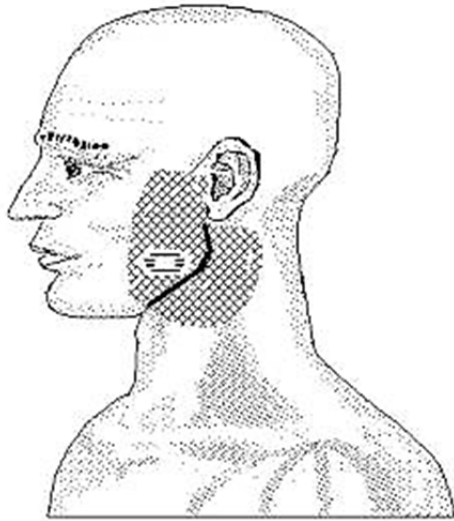
**Temporalis (middle A)**  
**(pattern may include upper teeth & jaw)**



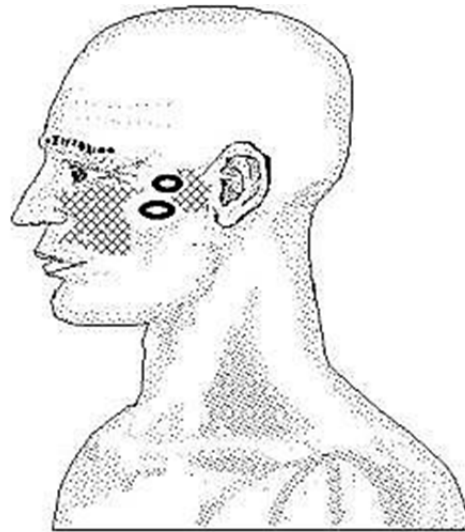
**Temporalis (middle B)**  
**(pattern may include upper teeth & jaw)**




**Temporalis (posterior supra auricular)**



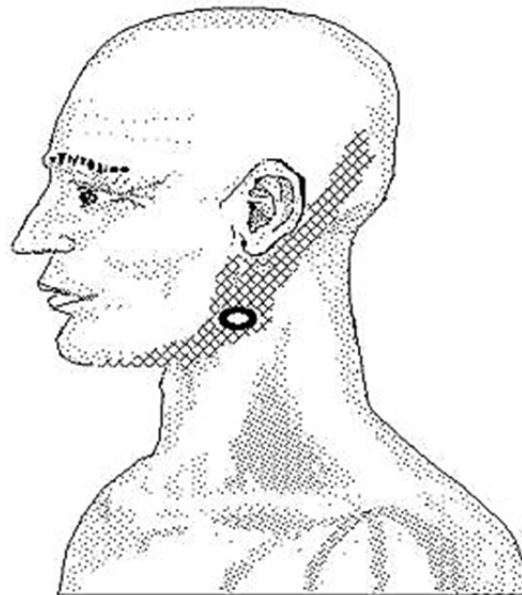
**Medial Pterygoid**  
 (pattern may also exist inside the jaw)



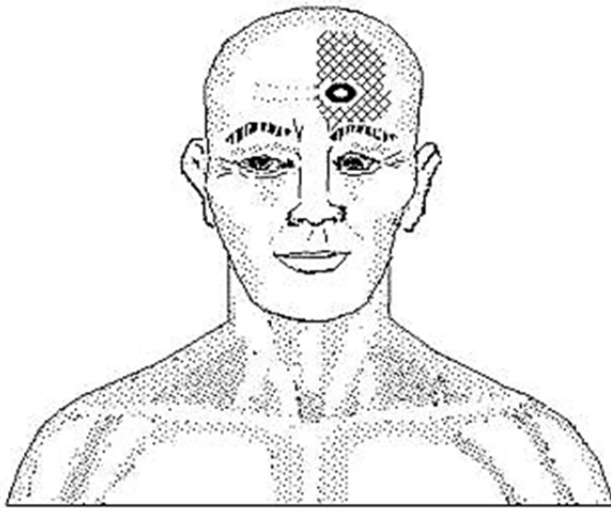
**Lateral Pterygoid**



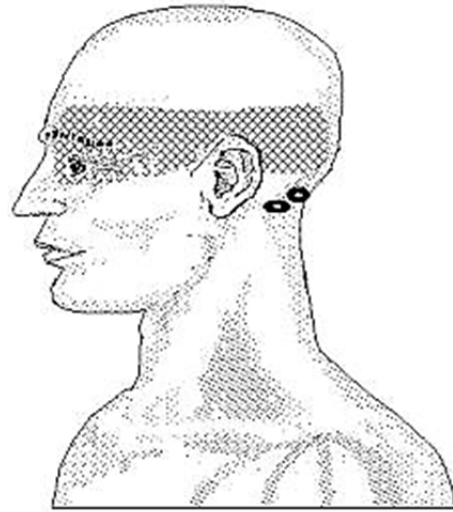
**Anterior Digastric**  
 (pattern may include upper teeth & jaw)



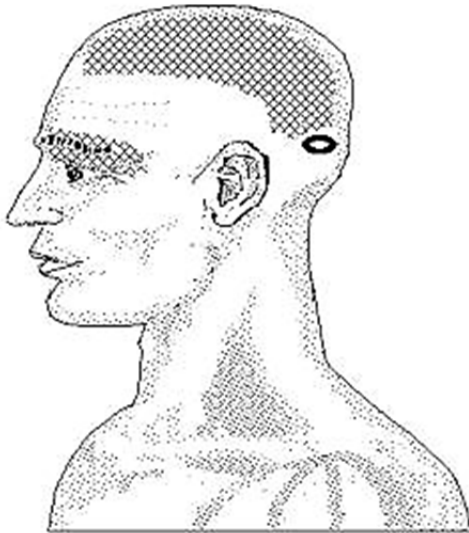
**Posterior Digastric**  
 (point accessible just under lower jaw)



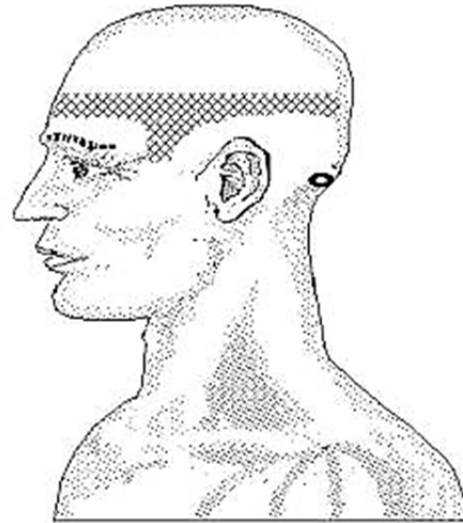
**Frontalis**



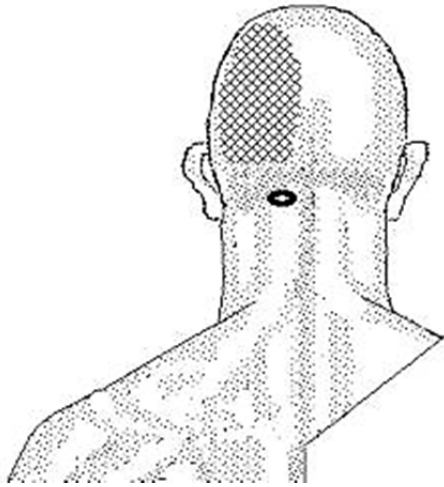
**Suboccipital Neck Extensors**



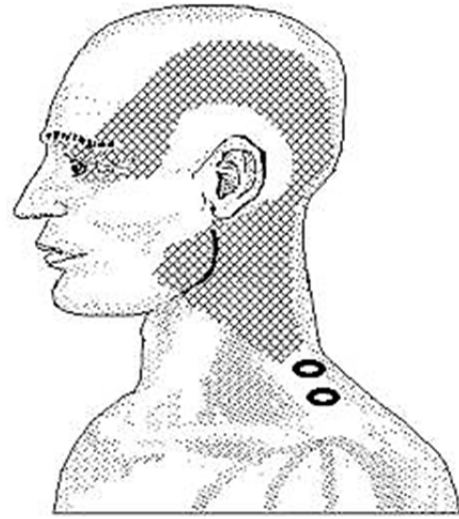
**Occipitalis**



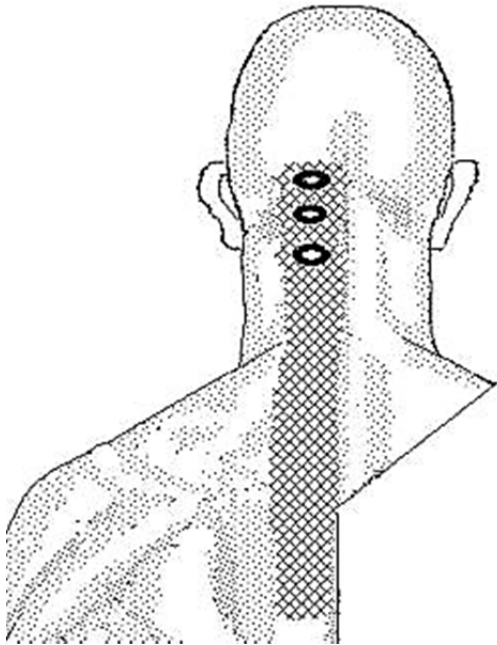
**Semispinalis Capitis**



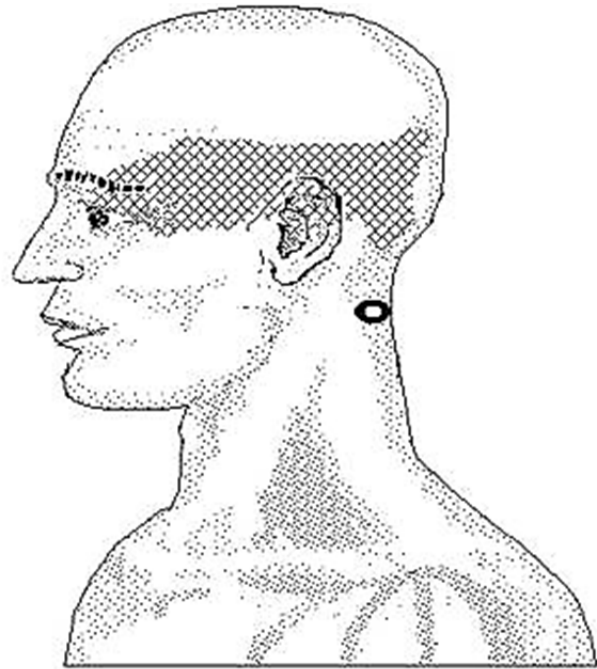
**Semispinalis Cervicis**



**Upper Trapezius A**

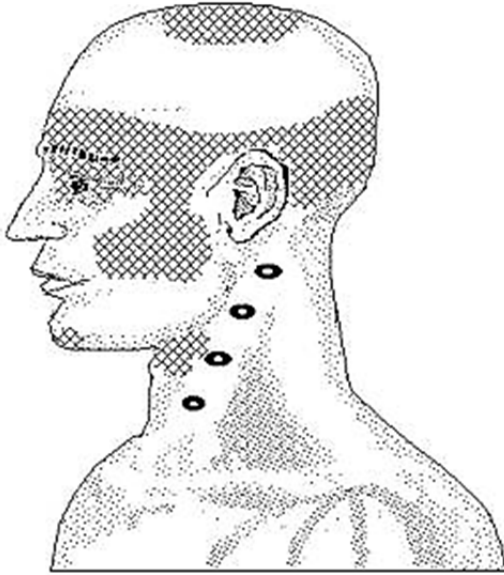


**Posterior Cervical Group**

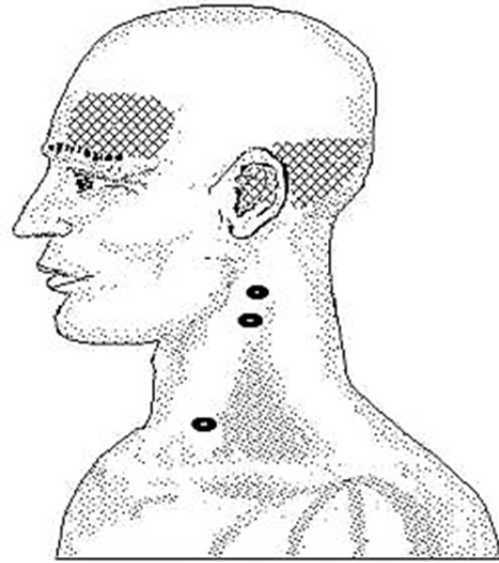


**Splenius Capitis A**

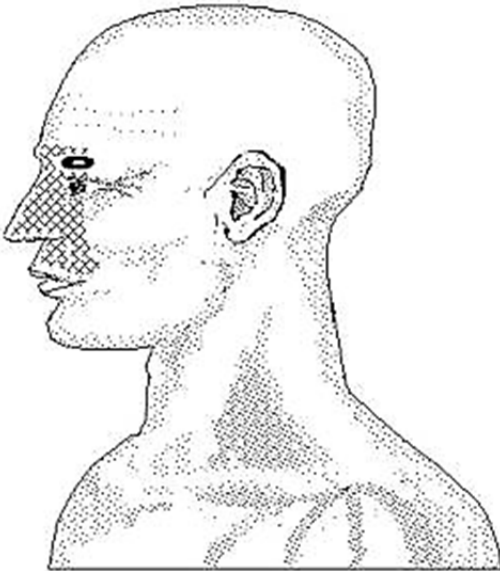




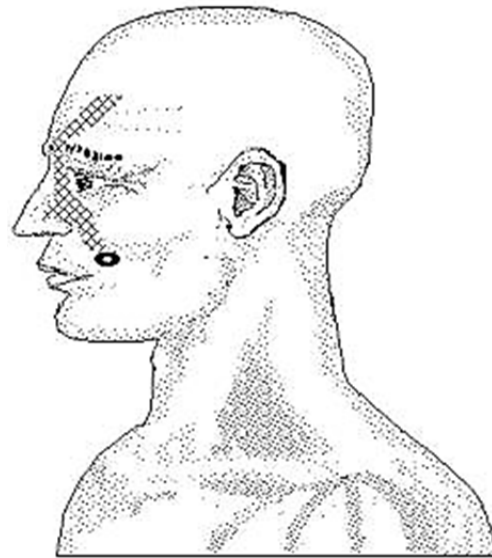
**Sternocleidomastoideus (superficial fibers)**



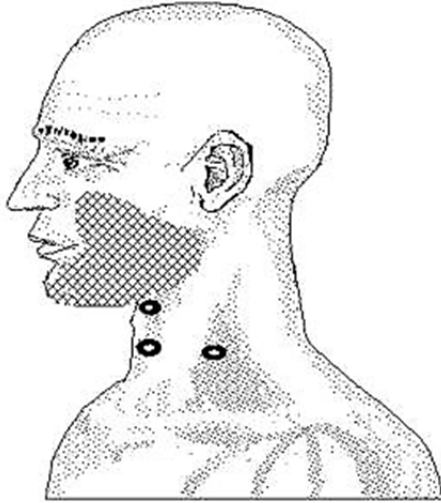
**Sternocleidomastoideus (deep fibers)**  
(forehead pattern may occur contra laterally)



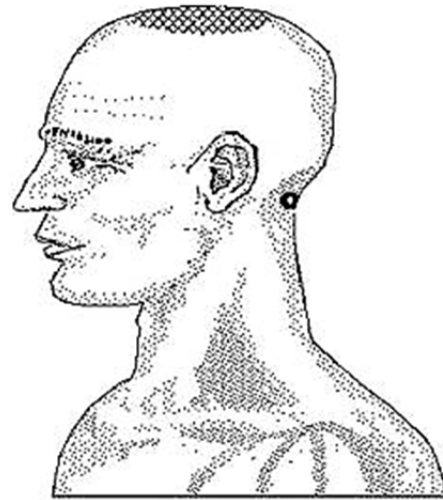
**Orbicularis Oculi**



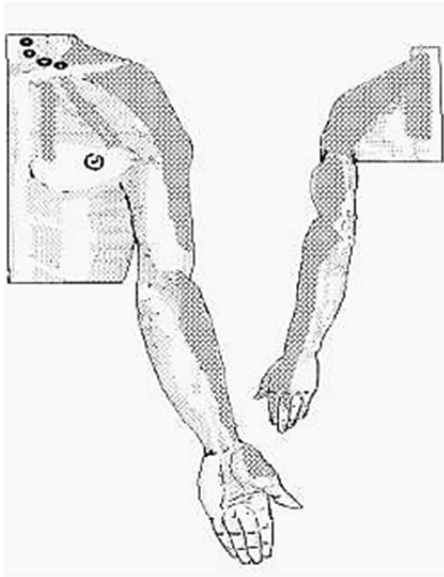
**Zygomaticus Major**



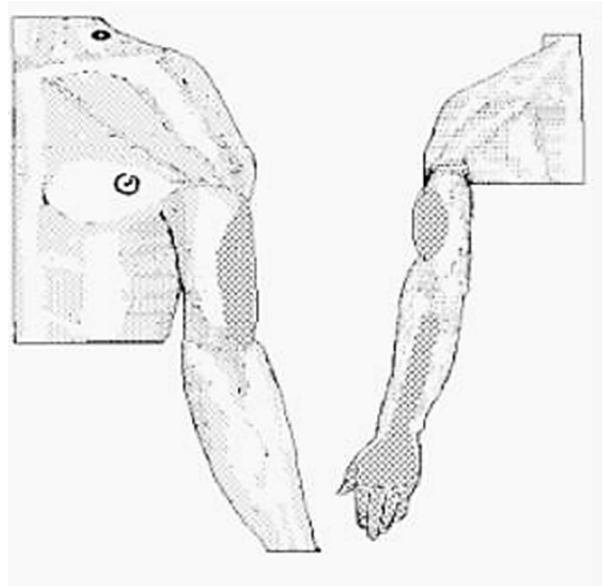
**Platysma**  
(pattern may also be under chin)



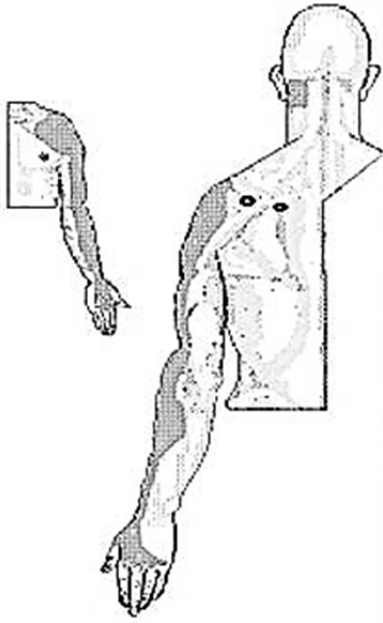
**Splenius Capitis B**



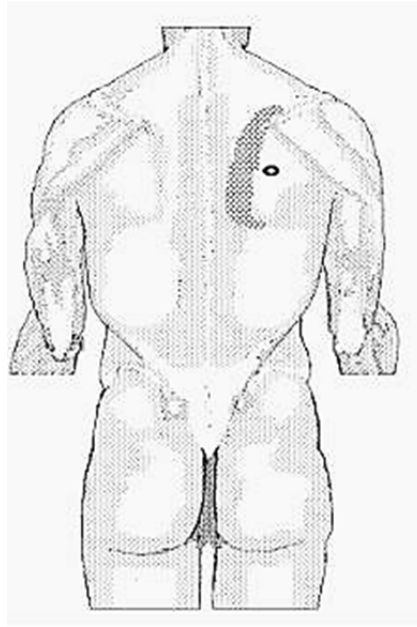
**Scalenus**  
(Anterior, Medius, & Posterior)



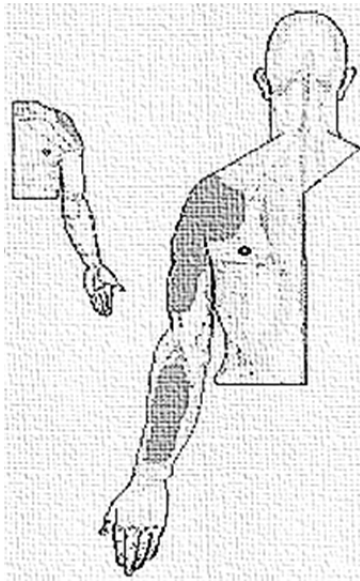
**Scalenus Minimus**



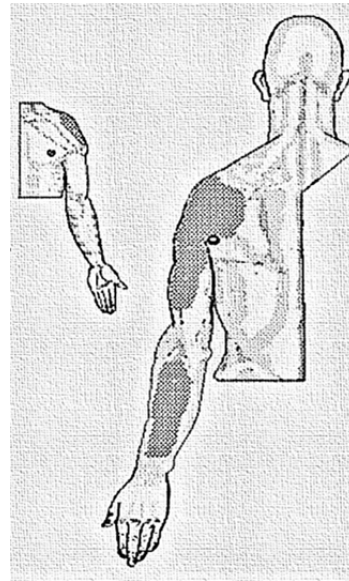
**Infraspinatus**



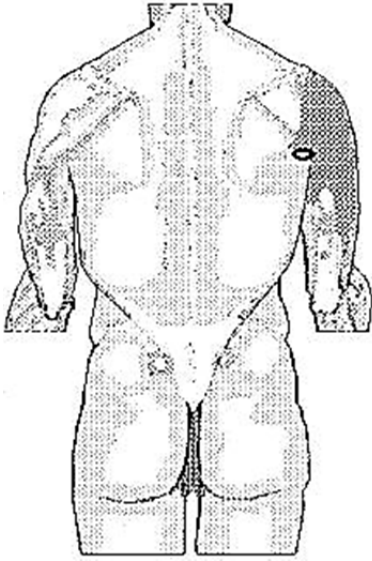
**Infraspinatus (abnormal)**



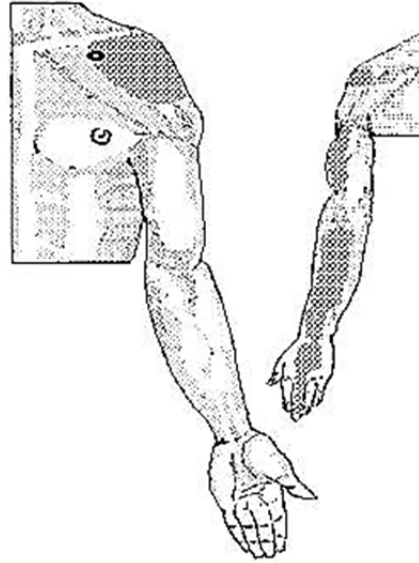
**Medial Teres Major**



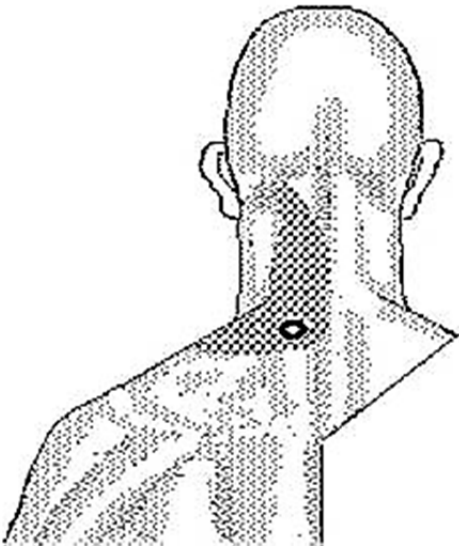
**Lateral Teres Major  
(point palpable in the posterior axilla area)**



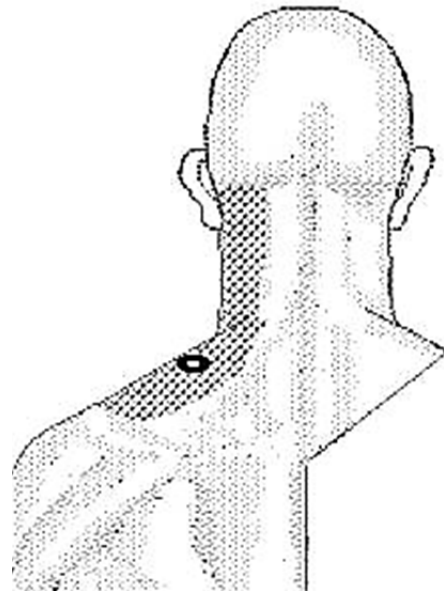
**Teres Minor**



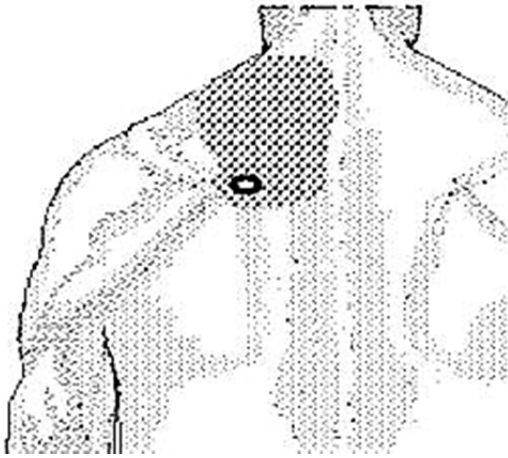
**Coracobrachialis**



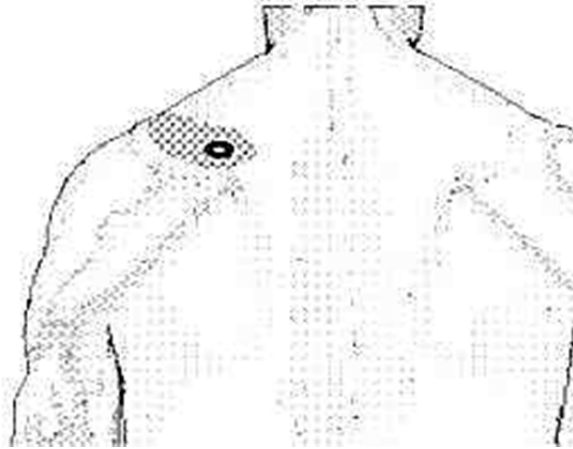
**Lower Splenius Cervicis**



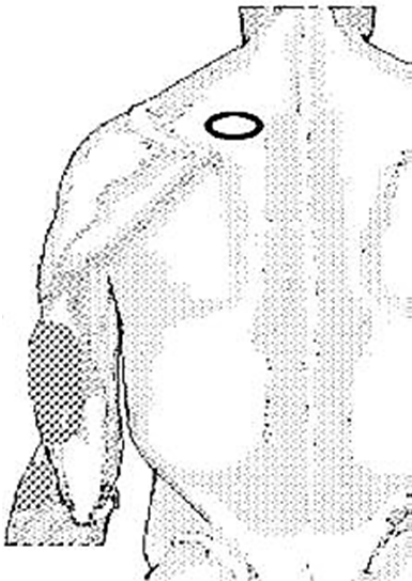
**Upper Trapezius B**



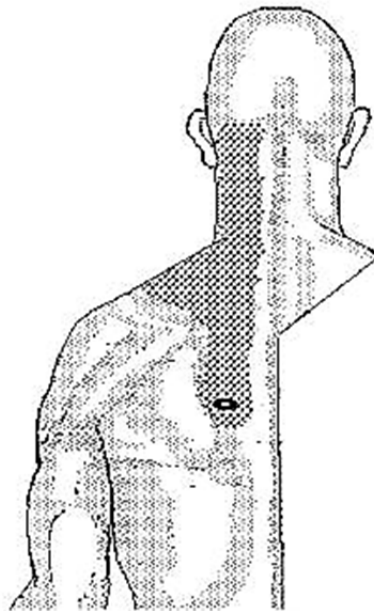
**Middle Trapezius A**



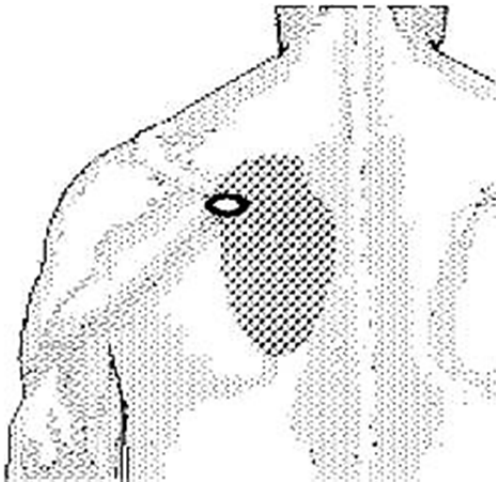
**Middle Trapezius B**



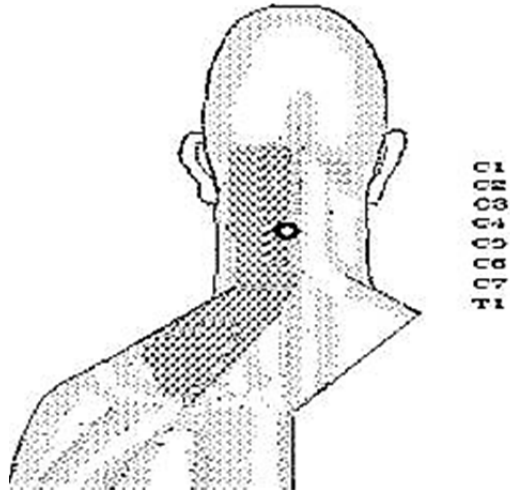
**Middle Trapezius C**  
("Goose flesh" occurs with pain)



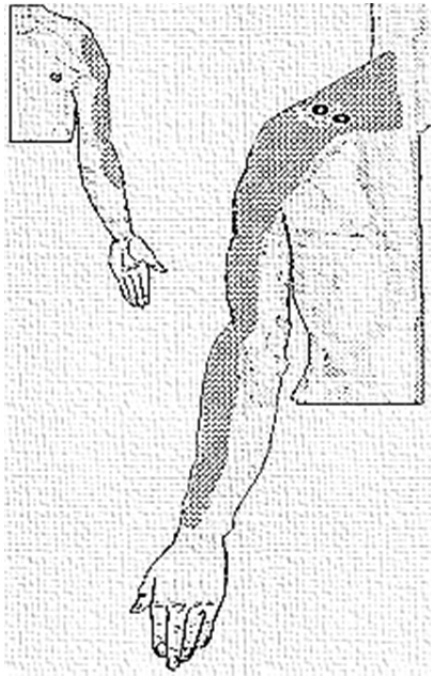
**Lower Trapezius A**



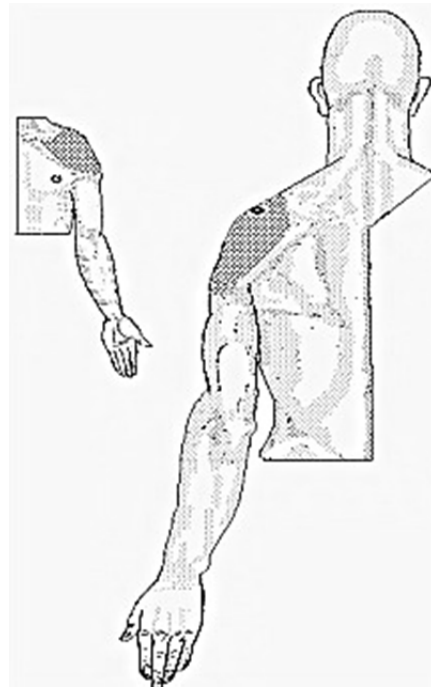
**Lower Trapezius B**



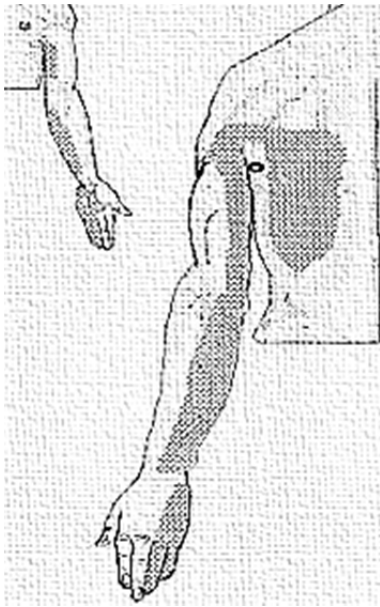
**Cervical Multifidus (C4-C5)**



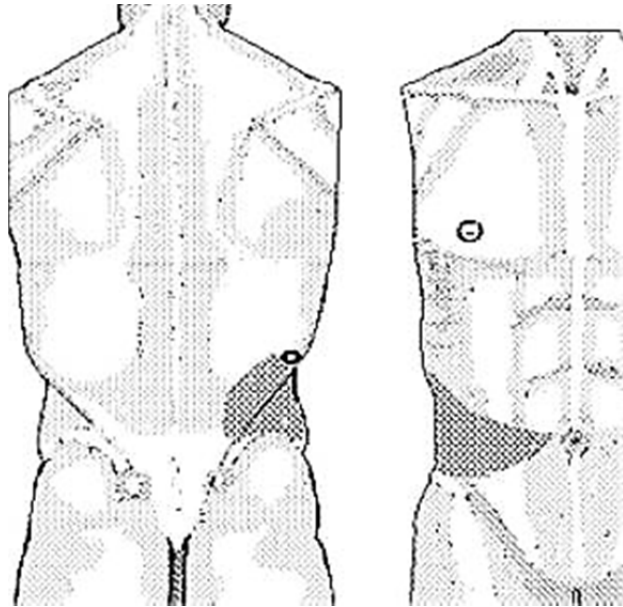
**Supraspinatus (muscle)**



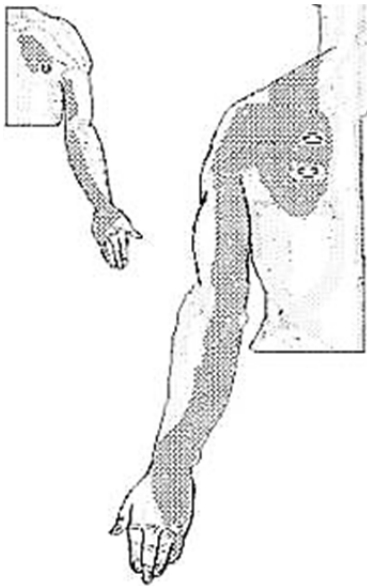
**Supraspinatus (tendon)**



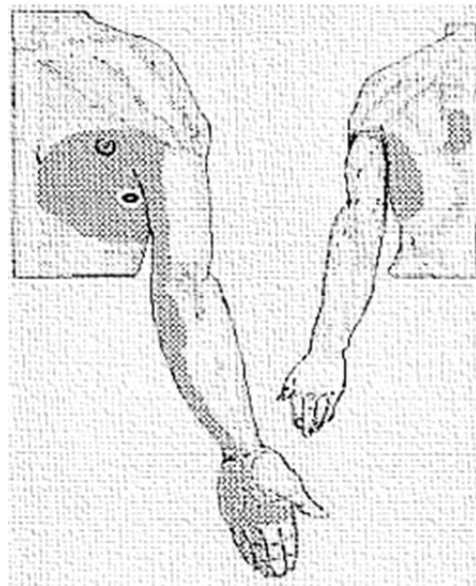
**Latissimus Dorsi (upper portion)**



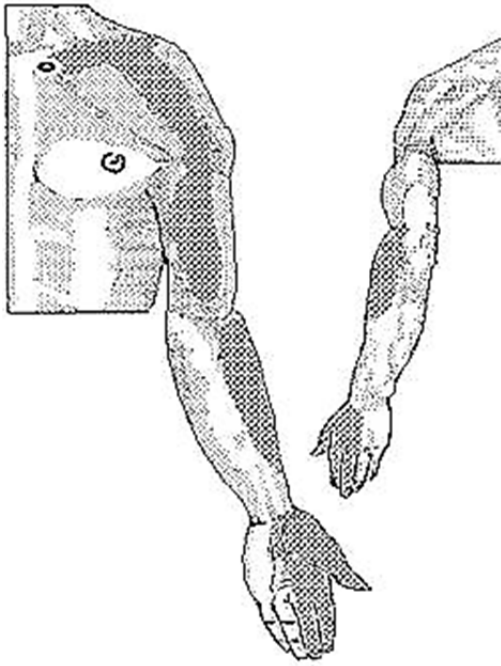
**Latissimus Dorsi (abnormal)**



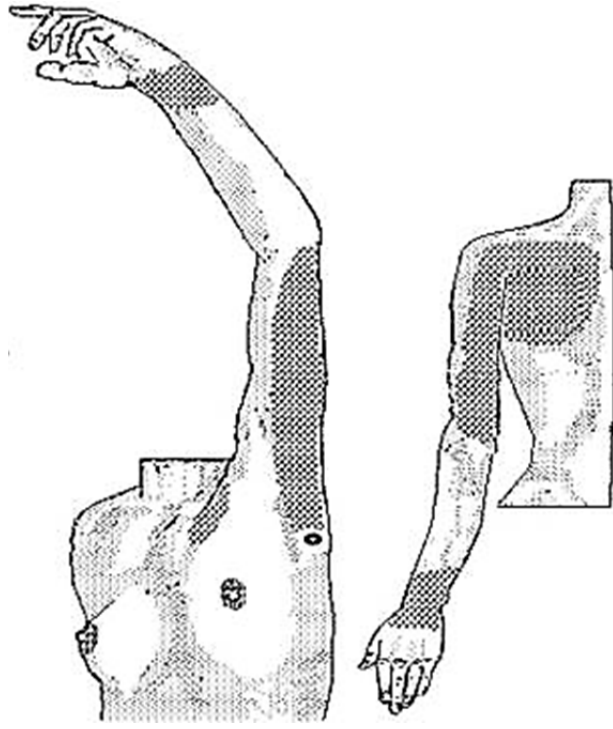
**Serratus Posterior Superior  
(points palpated with scapular abduction)**



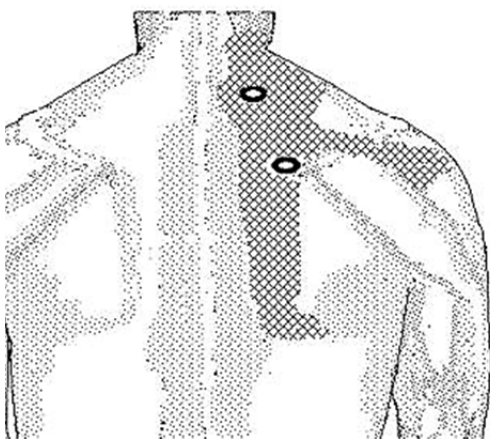
**Serratus Anterior**



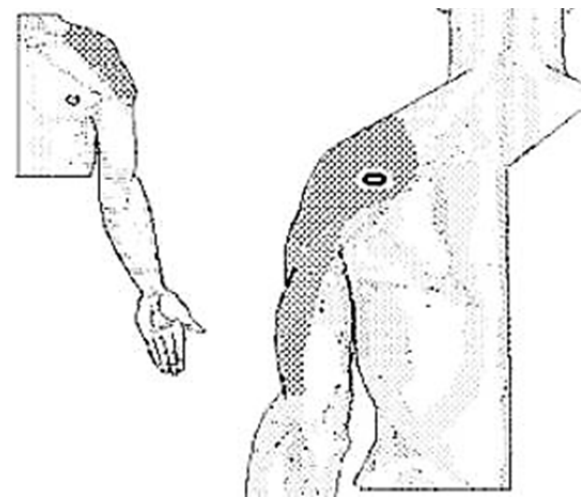
**Subclavius**



**Subscapularis**

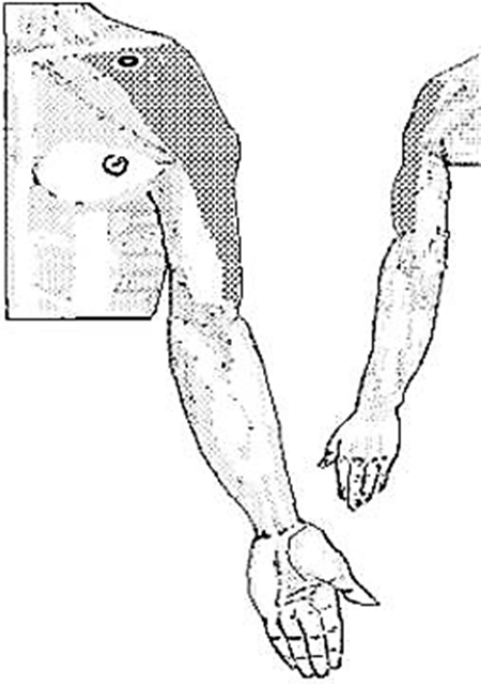


**Levator Scapulae**

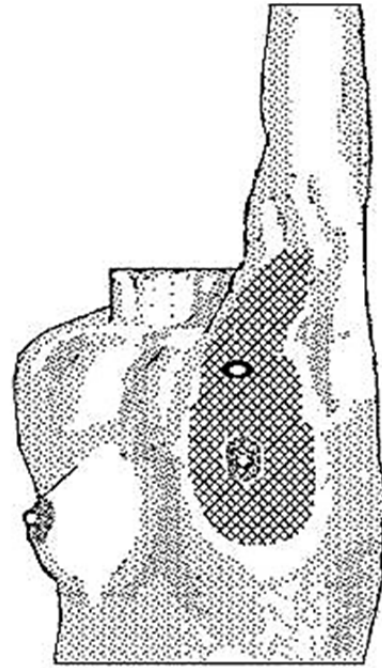


**Posterior Deltoid**

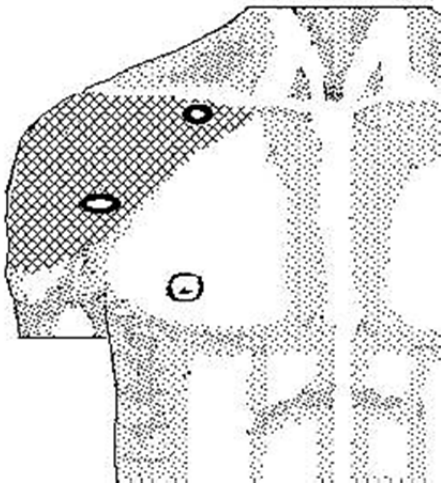




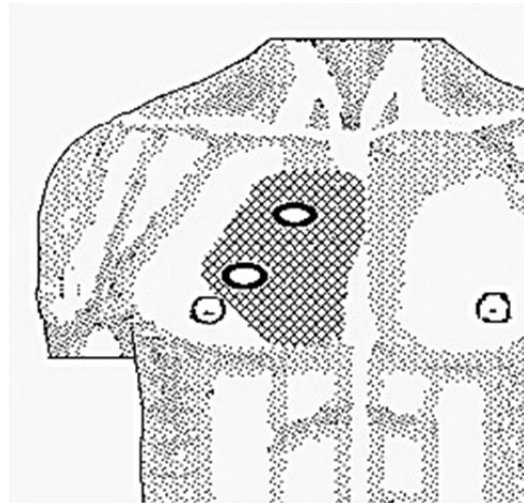
**Anterior Deltoid**



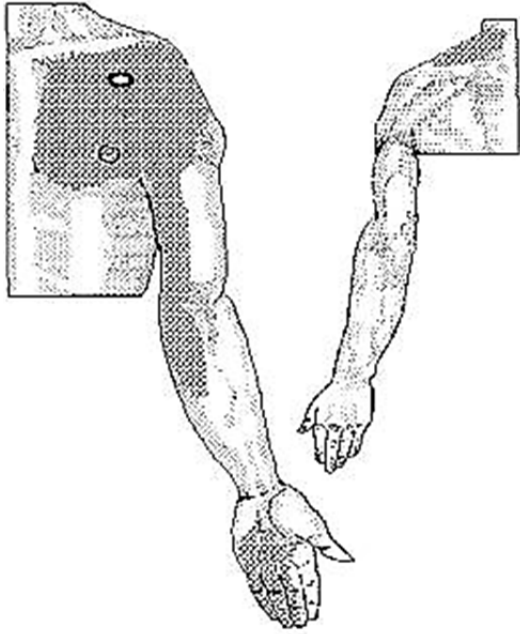
**Pectoralis Major**



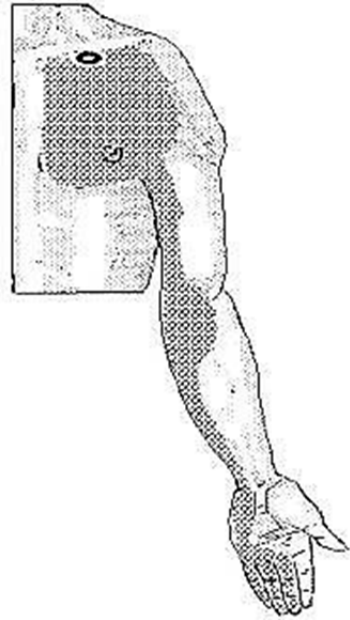
**Pectoralis Major (clavicular fibers)**



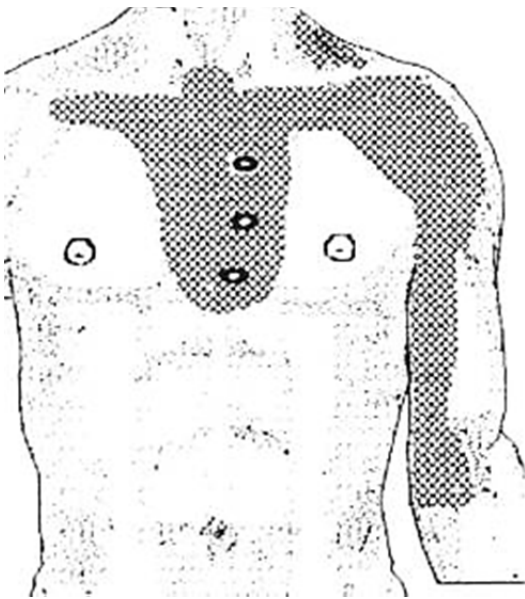
**Pectoralis Major (parasternal fibers)**



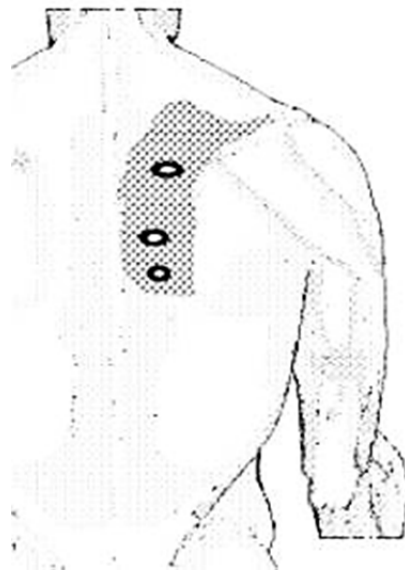
**Pectoralis Major (sternal portion)**



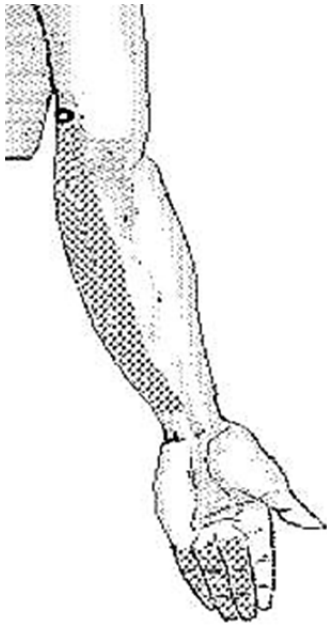**Pectoralis Minor**



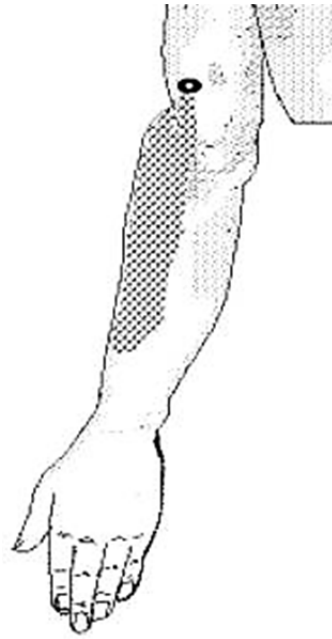
**Sternalis**



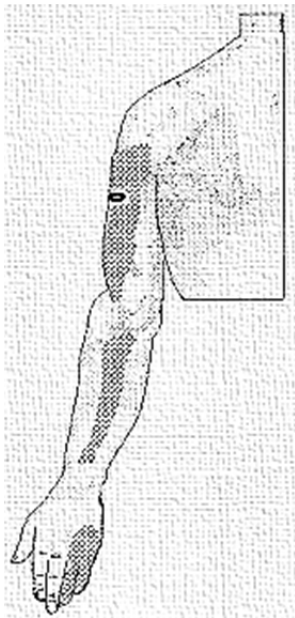
**Rhomboids**



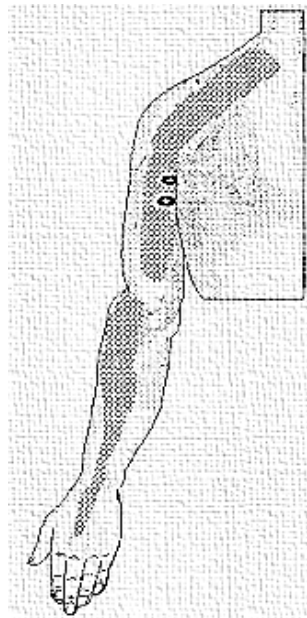
**Medial Triceps (deep fibers)**



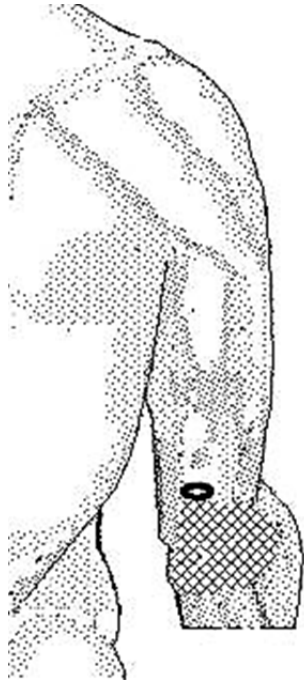
**Medial Triceps (lateral fibers)**



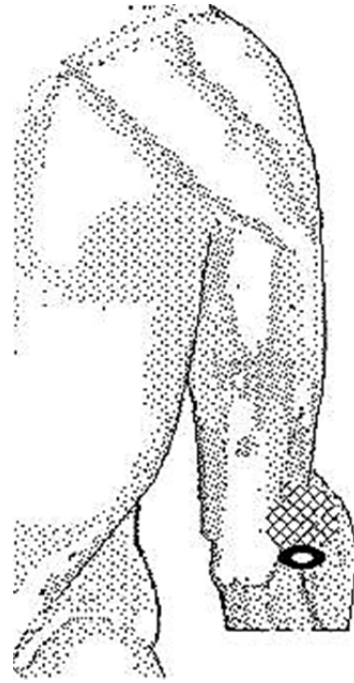
**Lateral Triceps**



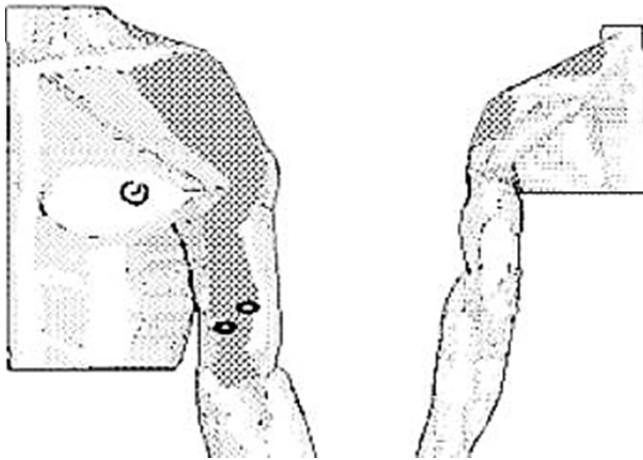
**Triceps (long head)**



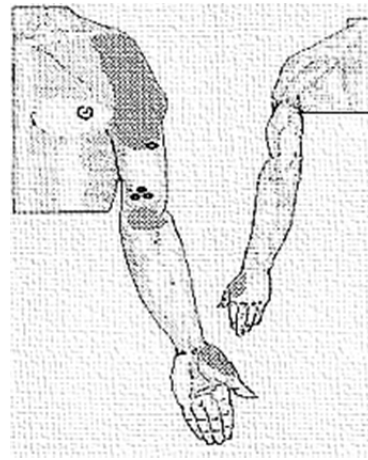
**Distal Medial Triceps**



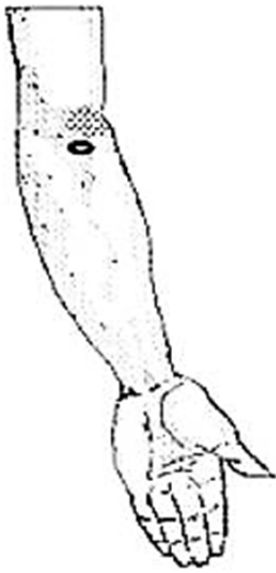
**Anconeus**



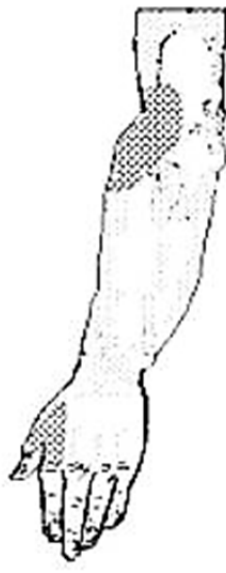**Biceps Brachii**



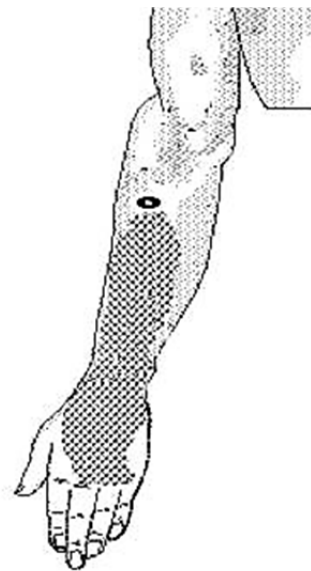
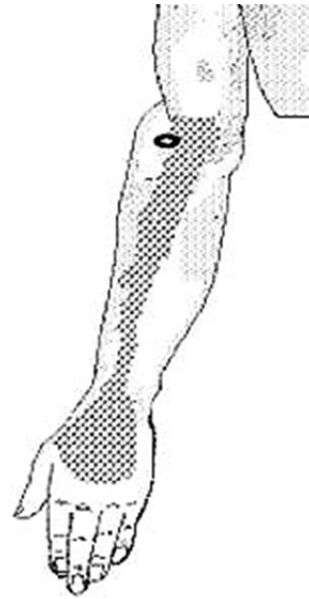**Brachialis (superior & inferior)**



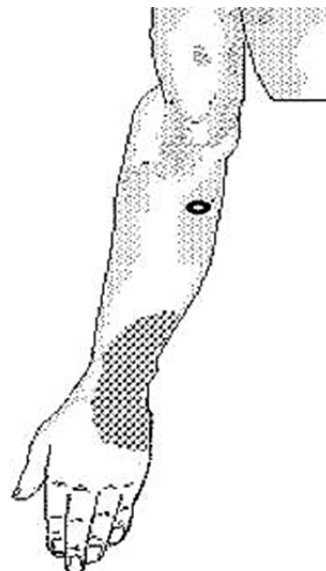
**Supinator**



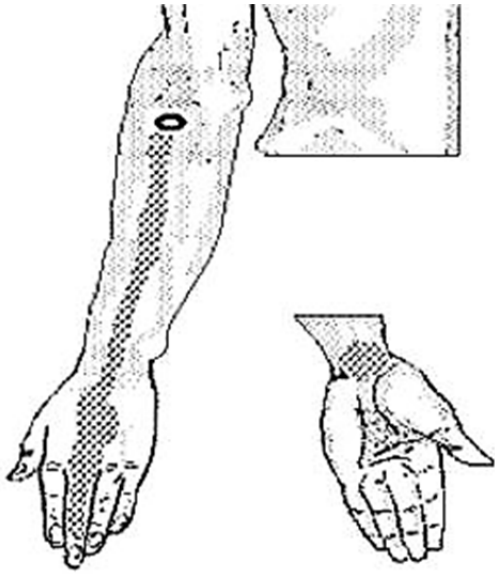
**Extensor Carpi Radialis Longus**



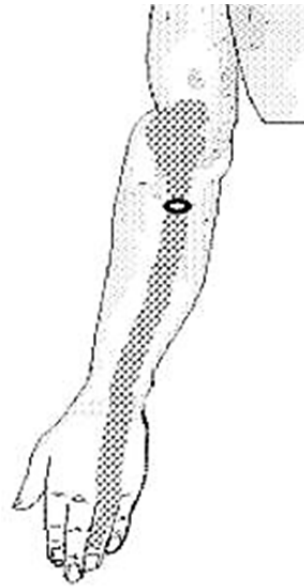**Extensor Carpi Radialis Brevis**



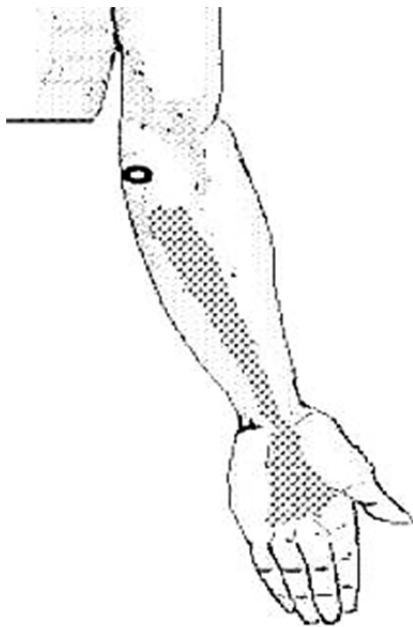
**Extensor Carpi Ulnaris**



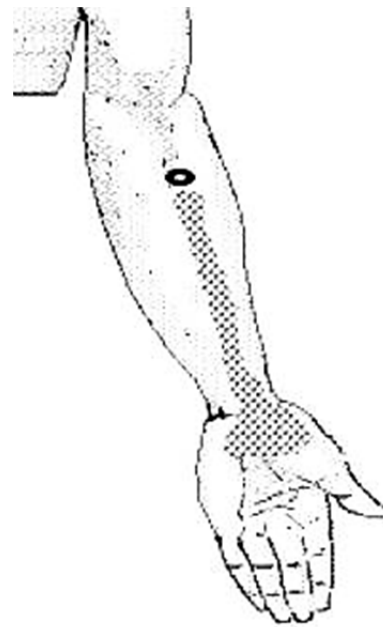
**Middle Finger Extensor**



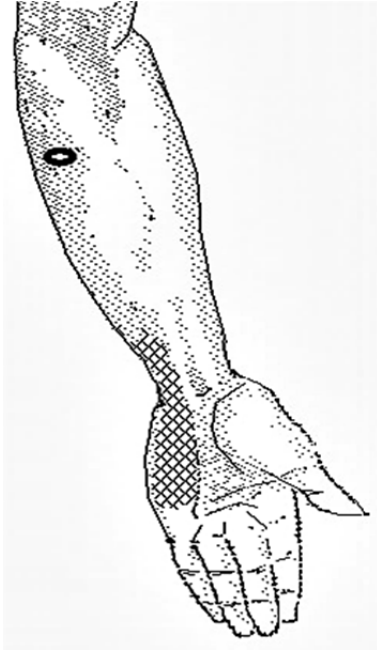
**Fourth Finger Extensor**



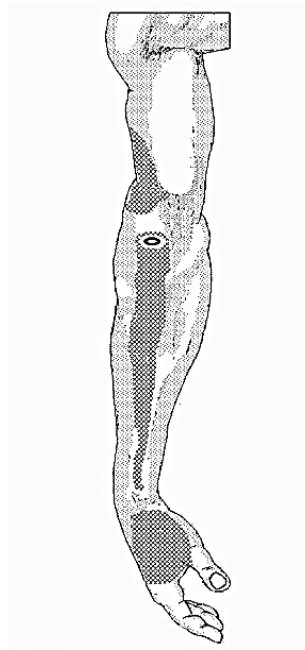
**Palmaris Longus**



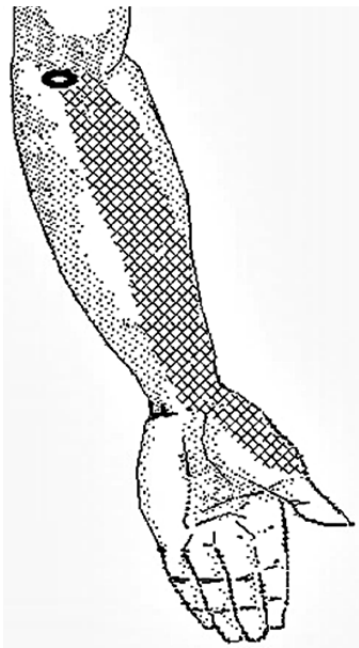
**Flexor Carpi Radialis**



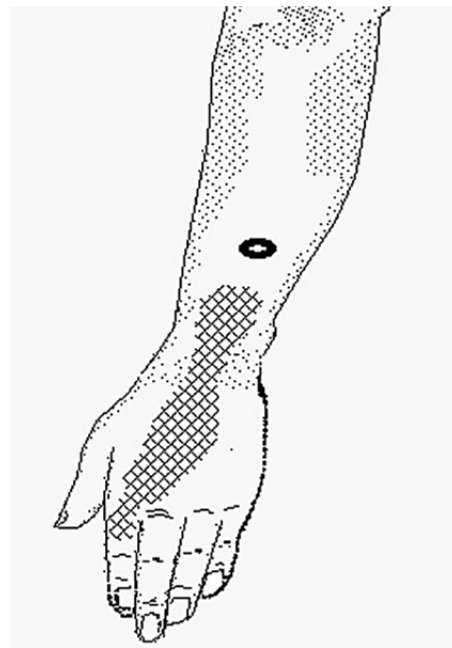
**Flexor Carpi Ulnaris**



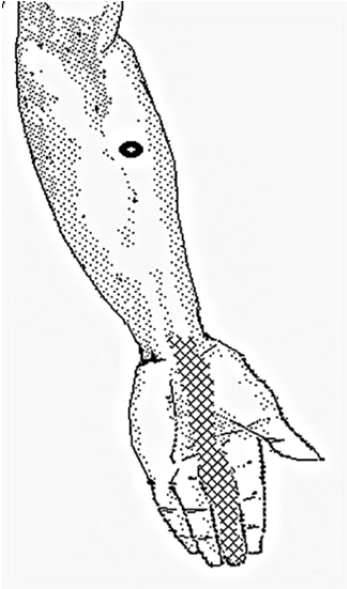
**Brachioradialis**



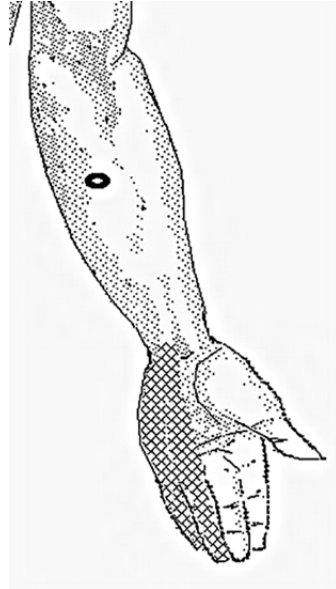
**Pronator Teres**



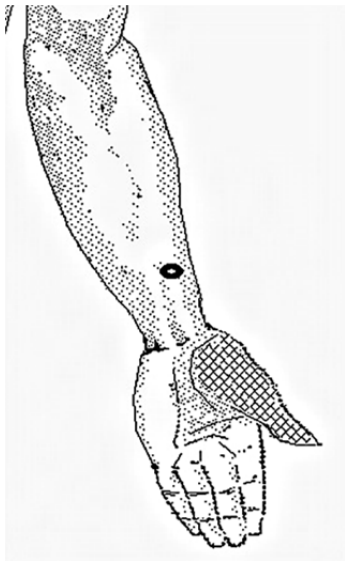
**Extensor Indicis Proprius**



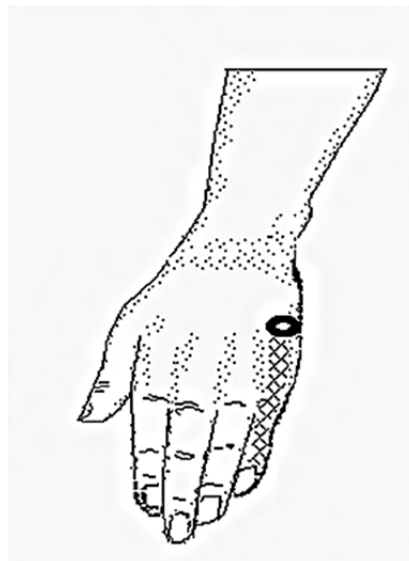**Flexor Digitorum Sublimis (radial head)**



**Flexor Digitorum Sublimis (humeral head)**

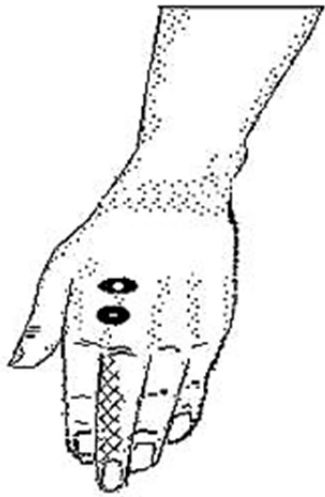


**Flexor Pollicis Longus**

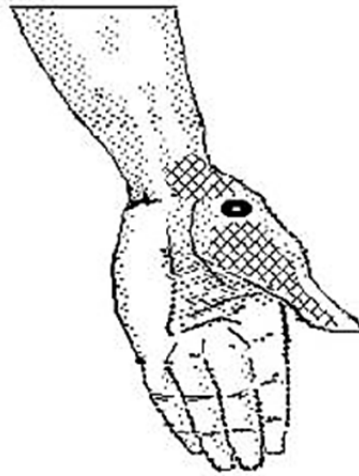


**Abductor Digiti Quinti**

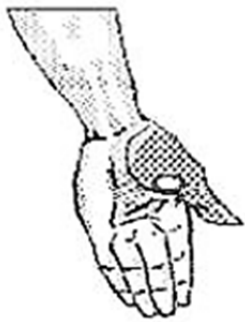



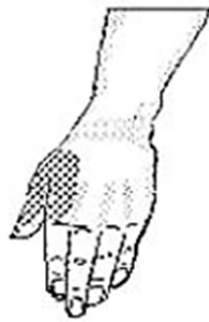**Second Dorsal Interosseus**



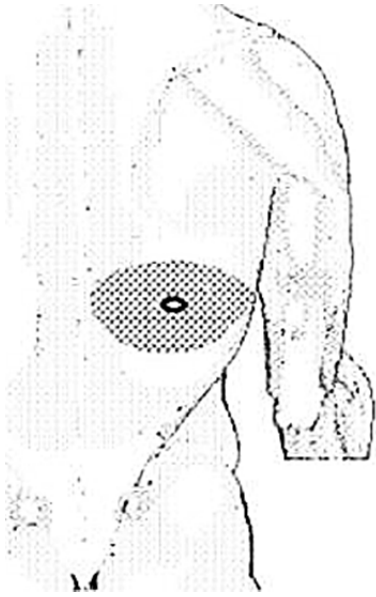
**Opponens Pollicis**



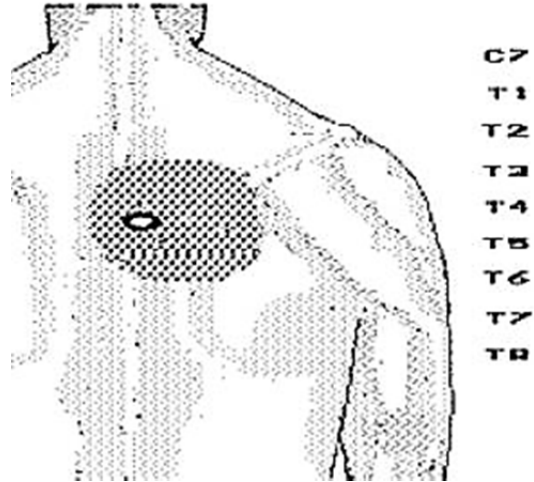
**Adductor Pollicis**



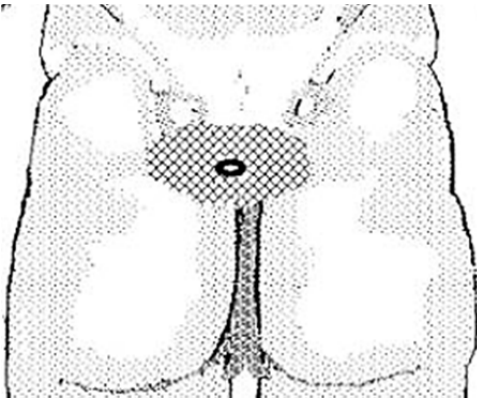
**First Dorsal Interosseus**



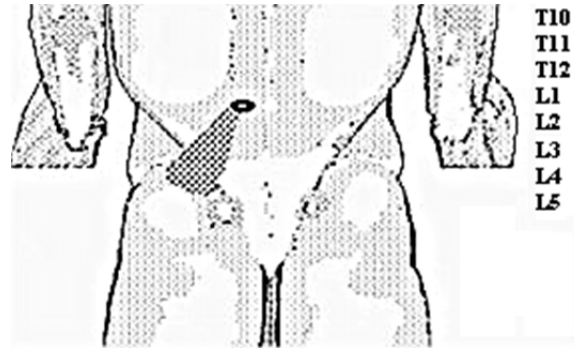
**Serratus Posterior Inferior**



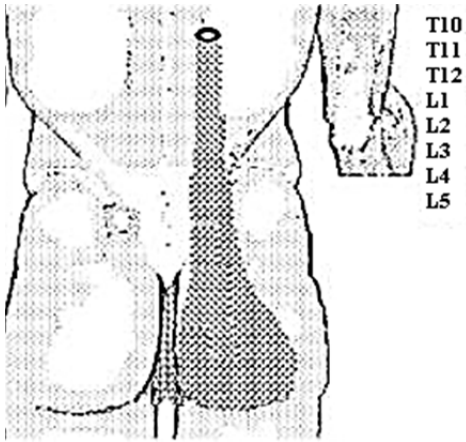
**Multifidus (T4-T5)**



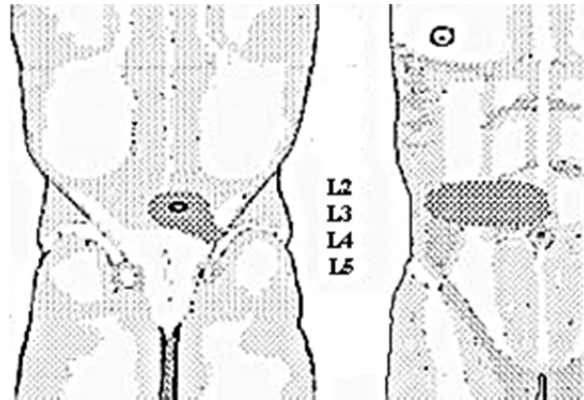
**Multifidus (S4)**



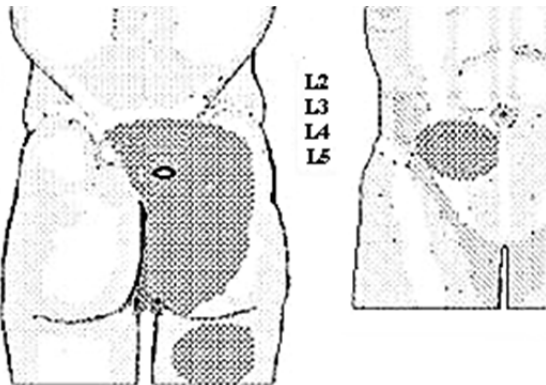
**Longissimus Thoracis (L1)**



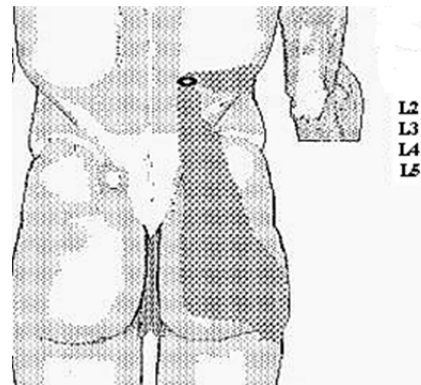
**Longissimus Thoracis (T10-T11)**



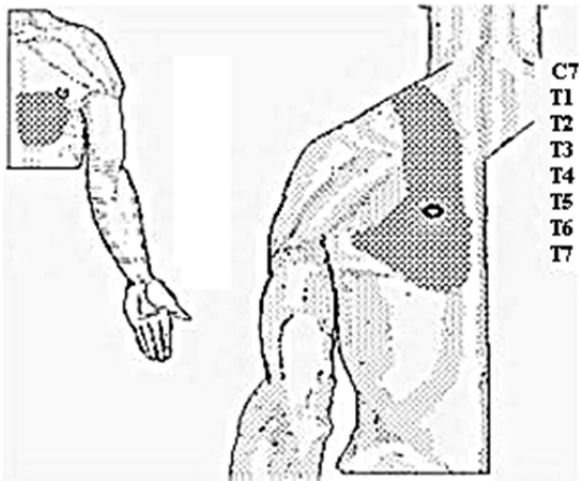
**Multifidus (L2-L3)**



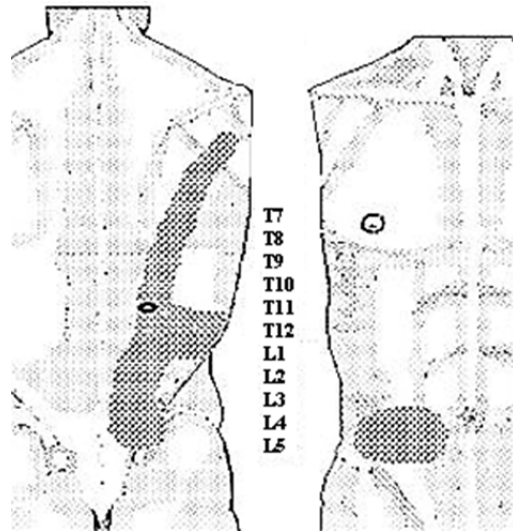
**Multifidus (S1-S2)**



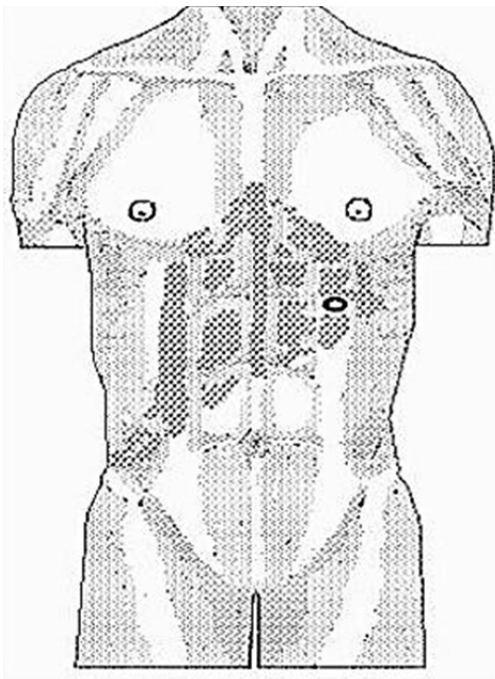
**Iliocostalis Lumborum (L1)**



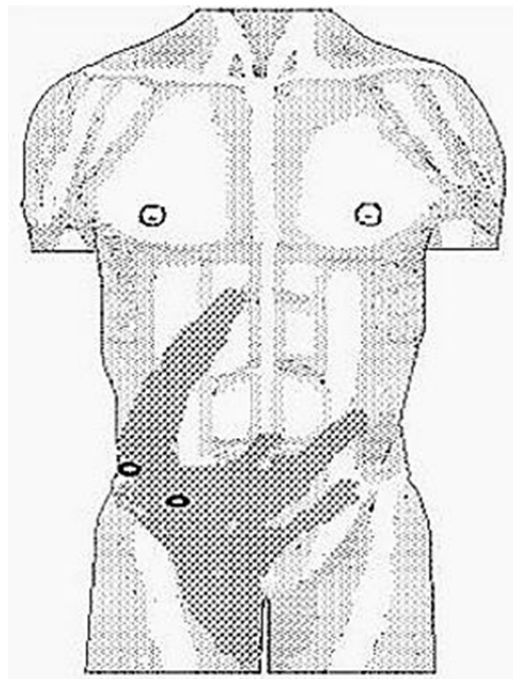
Iliocostalis Thoracis (T6)



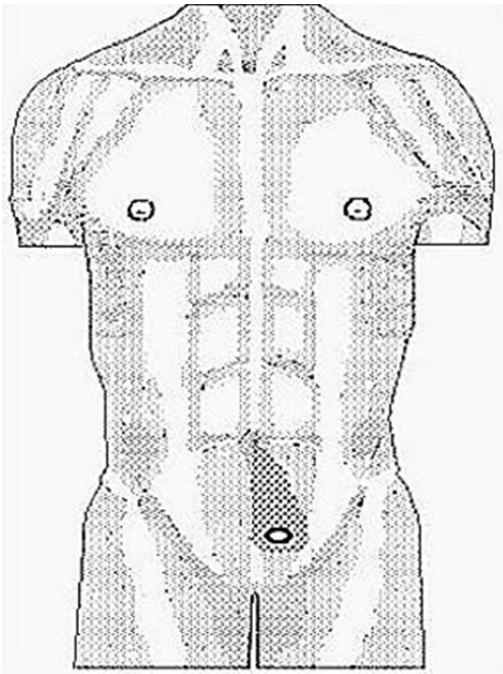
Iliocostalis Thoracis (T11)



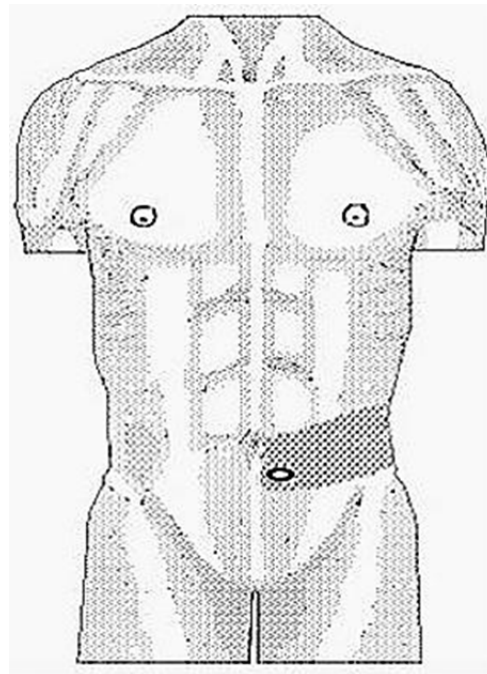
External Oblique A



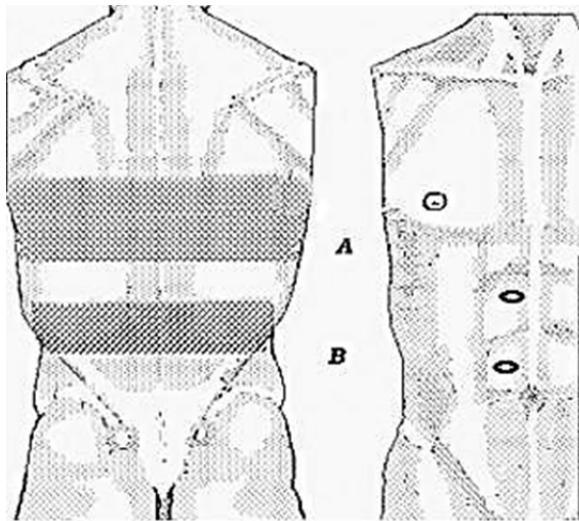
External Oblique B



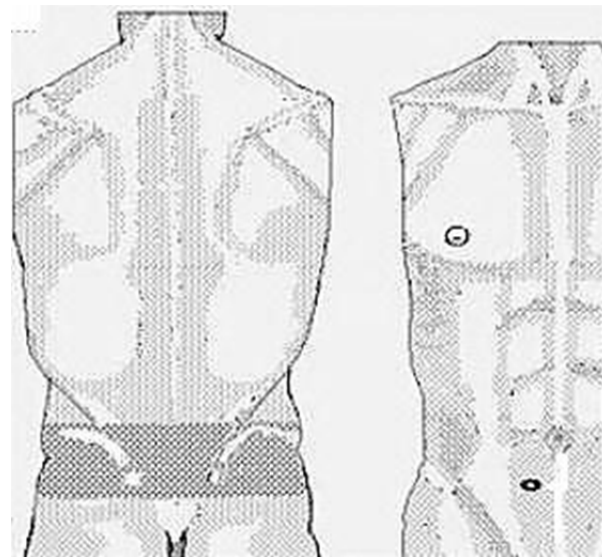
**Pyramidalis**



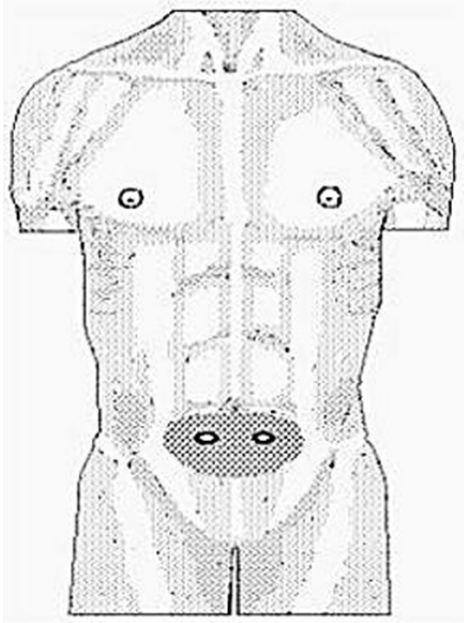
**McBurney's Point**



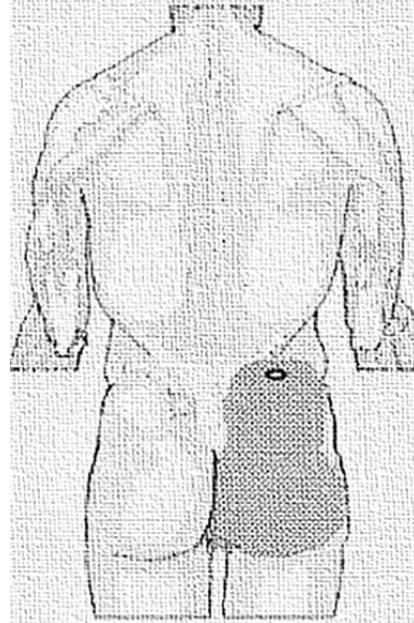
**A. Upper Rectus Abdominis**  
**B. Middle Rectus Abdominis**



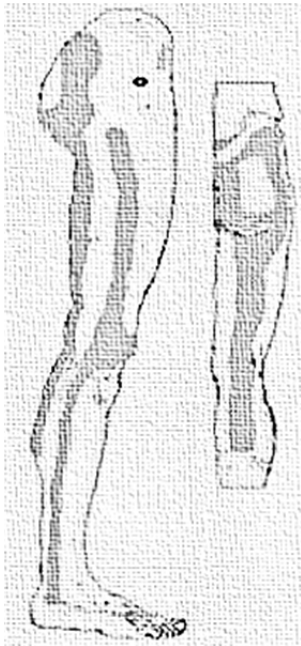**Lower (Caudal) Rectus Abdominis**



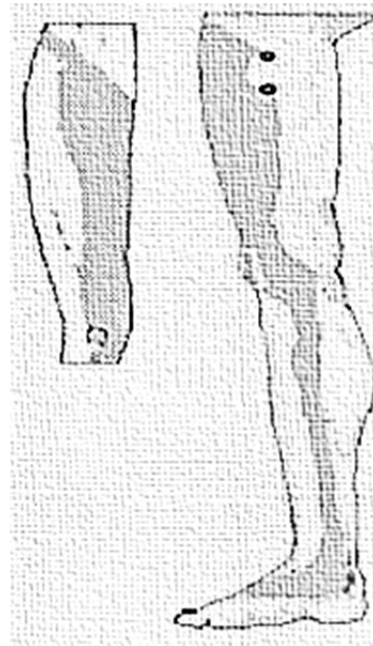
**Dysmenorrhea**



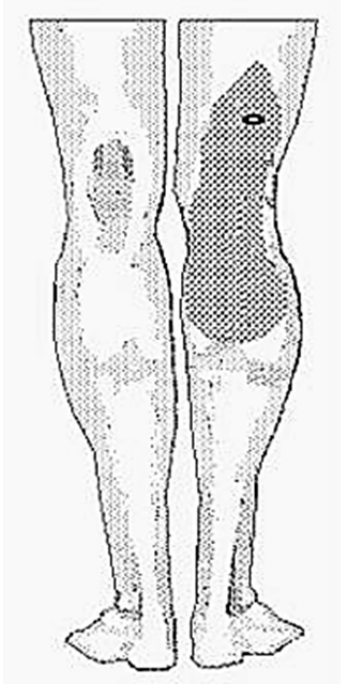
**Gluteus Medius**



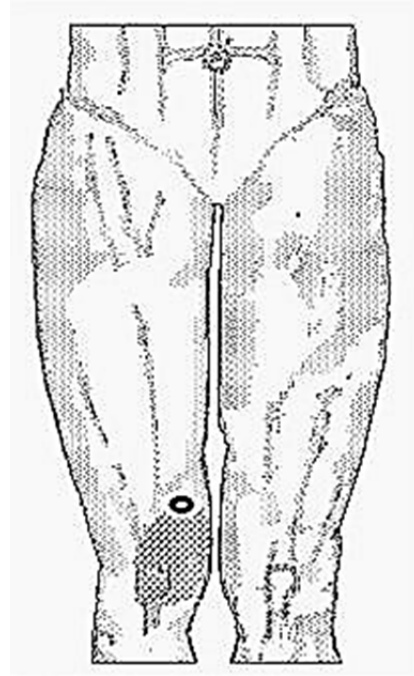
**Gluteus Minimus**



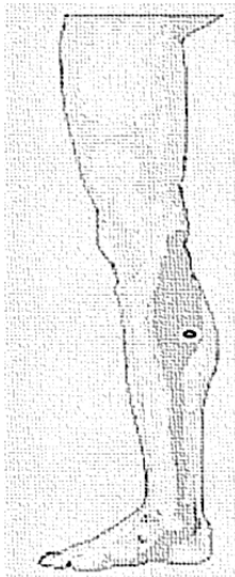**Adductor Longus**



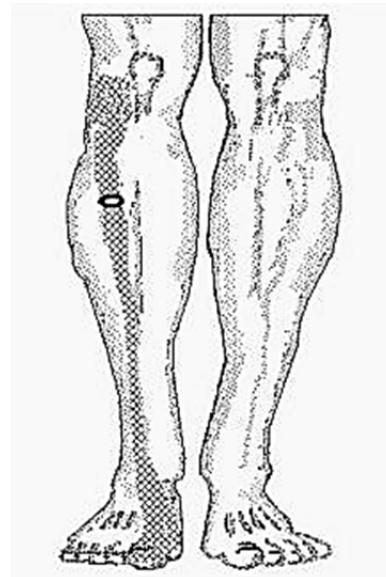
**Biceps Femoris**



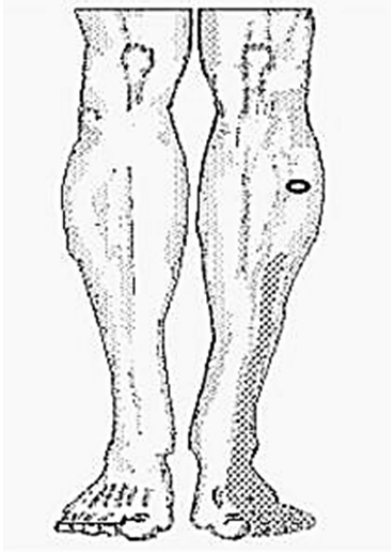
**Vastus Medialis**



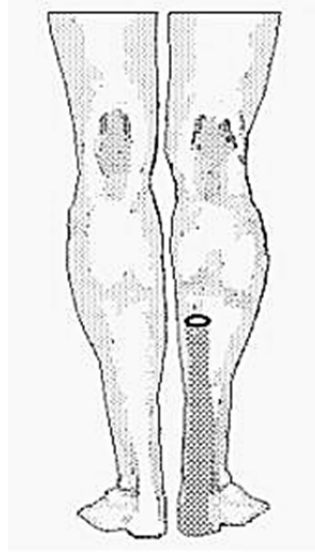
**Gastrocnemius**




**Anterior Tibialis**



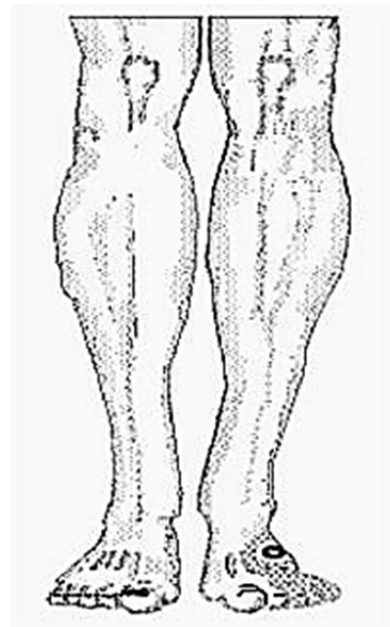
**Long Toe Extensors**



**Soleus**

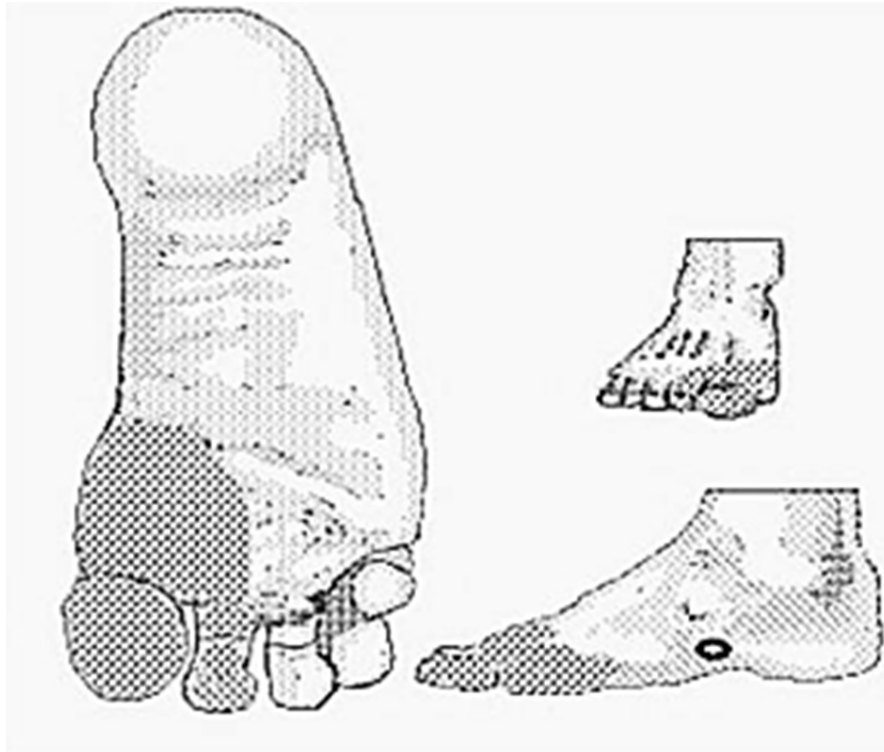


**Peroneus Longus**



**Short Toe Extensors**





**Abductor Hallucis**